

Acute Cerebellitis Following Opium Intoxication: A Case Report and Literature Review

Firozeh Hosseini,¹ and Ali Nikkhah^{2,*}

¹Besat Hospital, Hamadan University of Medical Sciences, Hamadan, IR Iran

²Pediatric Neurology Department, Mazandaran University of Medical Sciences, Sari, IR Iran

*Corresponding author: Ali Nikkhah, Department of Pediatric Neurology, Faculty of Medicine, Mazandaran University of Medical Sciences, Sari, IR Iran. Tel: +98-1144224339, Fax: +98-11-32353061, +98-9112271352, E-mail: alinik52@yahoo.com

Received 2016 September 07; Revised 2016 November 28; Accepted 2016 December 03.

Abstract

Introduction: Acute cerebellitis (AC) is a rare potentially life-threatening condition in children. Some viral infections, vaccines and neuroimmunologic disorders are the most common causes of AC. Opium poisoning is an unusual cause of this condition.

Case presentation: A 2-year-old girl was referred with loss of consciousness. She was ataxic just a few minutes after opium ingestion and after 1 hour, she became unconscious. We only found pinpoint pupils. After naloxone drip, her condition had been better but she was still obtunded and her urine was positive for opium products (morphine). MRI of the brain showed marked bilateral cerebellar swelling that respond to high-dose steroid dramatically.

Conclusion: This case shows that opium intoxication should be considered as a rare cause of acute cerebellitis in children.

Keywords: Acute Cerebellitis, Opium Intoxication, Opioid, Children

1. Introduction

Acute cerebellitis (AC) is an uncommon form of cerebellar inflammatory disorder that can cause acute cerebellar dysfunction. In children, AC is usually due to viral infections, vaccination, lead intoxication, trauma and neuroimmunologic disorders (1). Severe form of AC is very rare in children and this fulminant cerebellitis can lead to death (2). Involved patients present decreased levels of consciousness, vomiting, hypotonia, fever and ataxia (1, 2). Brain Magnetic Resonance Imaging (MRI) is the method of choice for determining cerebellar involvement that could indicate diffuse edema with or without high signal cortical and white matter lesions in cerebellar hemispheres (3, 4). Unfortunately, unintentional opium poisoning in young infants and toddlers is a relatively common cause of acute loss of consciousness with respiratory depression and apnea (5, 6). There is a specific and characteristic clinical feature (pinpoint pupils) in opium intoxication that allows physicians to reach this diagnosis (7). Isolated cerebellar involvement, especially acute cerebellitis due to opium intoxication, is extremely rare in children and there is only one case report in the literature (4). However another case has been reported with toxic encephalopathy and cerebellar involvement (8). Here, we report on a 2-year-old child with acute cerebellitis following opium (Teriac) poisoning.

2. Case Presentation

A previously normal 2-year-old girl was referred to our emergency department with loss of consciousness. On admission, she was stuporous but her respiration was normal. Based on her parents' report, she was ataxic just a few minutes after opium ingestion, and after 1 hour, she became unconscious. On physical examination, we only found pinpoint pupils and other aspects of examination were unremarkable. She was afebrile and there wasn't any history of seizure. She had frequent vomiting before loss of consciousness. Temperature was 37.2°C (axillary), pulse rate: 100/minute, respiratory rate: 20/minute and blood pressure was 85/50 mmHg. On laboratory data, blood gas, blood glucose and other biochemistry tests were normal. The following parameters were also measured: whole blood count (WBC): 13500 polymorphonuclear leukocyte (PMN): 66%, hemoglobin (HBG): 12.9 g/dL, Plate: 293000/mm³, erythrocyte sedimentation rate (ESR): 15 mm/h. Based on these findings, our primary impression was toxic encephalopathy with exclusion of central nervous system (CNS) infections. We started cefotaxime, vancomycin and acyclovir for possible meningoenphalitis although naloxone was administered immediately. After naloxone drip, her condition improved and she was obtunded with response to touch yet her level of consciousness did not improve during 24 hours while her pupils had normal size. On the second day of admission, she was still obtunded and her primary blood culture was negative

but her urine was positive for opium products (morphine). We performed Magnetic Resonance Imaging (MRI) of the brain that showed marked bilateral cerebellar swelling without brainstem compression and cerebral white matter involvement that was compatible with acute cerebellitis (Figures 1 and 2). High dose intravenous methylprednisolone was administered at this point (30 mg/kg/d for 5 days). On the third day of admission (one day after methylprednisolone), our patient was conscious and after 5 days she was completely normal. Finally, on the sixth day of admission, we performed lumbar puncture and CSF analysis was normal (WBC: 1-2, RBC: 0-1, protein: 35mg/dl, glucose: 65 mg/dL). On the tenth day (4 days after lumbar puncture), CSF culture and polymerase chain reaction (PCR) for herpes virus were negative and at this point all antibiotics and acyclovir were discontinued and our patient was discharged with good condition and only mild ataxia during fast walking. Finally, she was completely normal on the second month follow up visit.

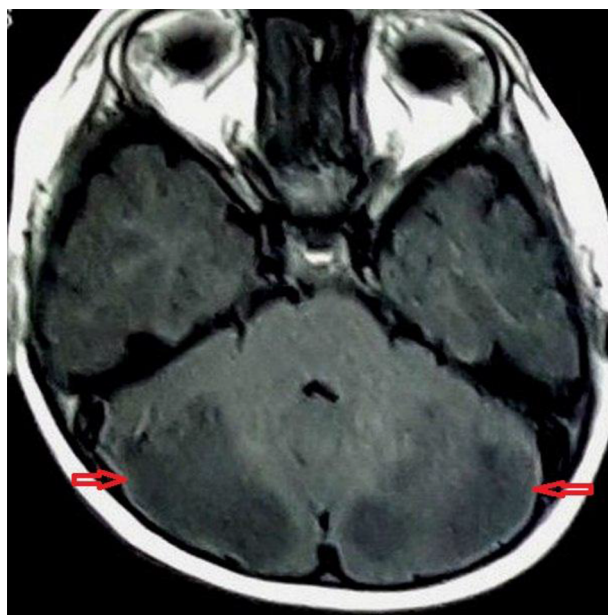


Figure 1. Axial T1 Magnetic Resonance Imaging Indicating Bilateral Symmetric Hypointensity in Cerebellar Hemispheres With Mild Narrowing of 4th Ventricle

3. Discussion and Review of the Literature

Acute cerebellitis is a rare inflammatory involvement of cerebellum that can be potentially life-threatening (2,9). There are certain viral infections (Epstein-Barr virus, varicella, mumps and HHV-6) as common systemic causes of

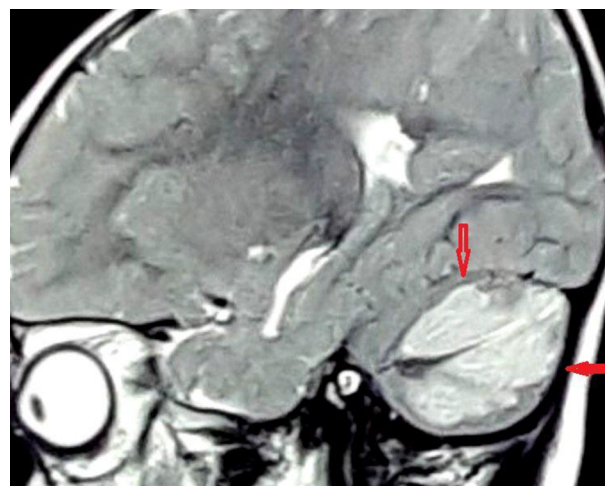


Figure 2. Sagittal T2 Magnetic Resonance Imaging Indicating Diffuse High-Signal Lesions in Cerebellar Hemispheres Consistent With Severe Cerebellar Edema

AC (3). Our patient was an interesting case because she developed AC after opium ingestion. There was not any evidence of other inflammatory disorders due to viruses or other agents. A 3-year-old girl was reported with AC after methadone poisoning by Mills et al. (4). They reported that this case had severe form of AC and hydrocephalus due to compression on fourth ventricle with watershed injuries (4). Fortunately, there was not hydrocephalus and/or fourth ventricle compression in our case. There are two case reports about leukoencephalopathy after opioid ingestion in children (8, 10). Anselmo et al. presented a 3-year-old boy with acute obstructive hydrocephalus due to massive cerebellar edema after accidental methadone poisoning (8). Nanan et al. reported a 14-year-old girl with multiple cerebral and cerebellar lesions after intentional morphine sulfate intoxication (10). Our case had AC with loss of consciousness and vomiting but there was not cerebral white matter involvement and there was severe edema in the cerebellum without any compression on 4th ventricle or herniation. There are various reports about AC and leukoencephalopathy due to heroin inhalation toxicity (11, 12). Our case referred to our unit with abrupt loss of consciousness after acute ataxia and pinpoint pupils that are characteristic features for opium poisoning and was initially managed with intravenous naloxone and supportive care. However, she did not respond appropriately to naloxone and because of continuity in loss of consciousness and frequent vomiting, brain MRI was performed that demonstrated diffuse cerebellar swelling without cerebral involvement, and AC diagnosis was suggested and after other investigations (CSF analysis, and CSF and blood cul-

tures), this diagnosis was confirmed. We did not find any evidence for bacterial infections and/or herpetic encephalitis based on clinical features and MRI findings. We couldn't perform LP before the fifth day of admission because of severe cerebellar edema as seen in MRI. Therefore, in this patient, methylprednisolone was administered after brain MRI and diagnosis of AC, and the patient became conscious immediately. Also, we did not find any evidence for other viral or inflammatory disorders based on clinical manifestations and laboratory findings. In the meantime, our patient was completely normal and all symptoms and signs had begun immediately after opium ingestion and we did not explain her condition with other disorders.

3.1. Conclusions

This case showed that opium intoxication should be considered as a rare cause of Acute Cerebellitis (AC), especially in children with continuity of encephalopathy and vomiting despite naloxone administration.

Acknowledgments

Authors appreciate staffs of PICU in Besat hospital of Hamadan University of Medical Sciences.

Footnotes

Conflict of Interests: None.

Funding/Support: Self-funded.

References

1. Ryan MM, Engle EC. Acute ataxia in childhood. *J Child Neurol.* 2003;**18**(5):309-16. [PubMed: [12822814](#)].
2. Levy EI, Harris AE, Omalu BI, Hamilton RL, Branstetter B, Pollack IF. Sudden death from fulminant acute cerebellitis. *Pediatr Neurosurg.* 2001;**35**(1):24-8. [PubMed: [11490187](#)].
3. Montenegro MA, Santos SL, Li LM, Cendes F. Neuroimaging of acute cerebellitis. *J Neuroimaging.* 2002;**12**(1):72-4. [PubMed: [11826604](#)].
4. Mills F, MacLennan SC, Devile CJ, Saunders DE. Severe cerebellitis following methadone poisoning. *Pediatr Radiol.* 2008;**38**(2):227-9. doi: [10.1007/s00247-007-0635-6](#). [PubMed: [17952429](#)].
5. Jabbehdari S, Farnaghi F, Shariatmadari SF, Jafari N, Mehregan FF, Karimzadeh P. Accidental children poisoning with methadone: an Iranian pediatric sectional study. *Iran J Child Neurol.* 2013;**7**(4):32-4. [PubMed: [24665315](#)].
6. Schelble DT. Phosgene and phosphine. In: Haddad LM, Shannon MW, Winchester J, editors. *Clinical Management of Poisoning and Drug Overdose*. Philadelphia: Saunders; 2007. pp. 640-7.
7. Taymori F, Cheraghali M. Epidemiological study of drug intoxication in children. *Acta Medica Iranica.* 2006;**44**(1):37-40.
8. Anselmo M, Campos Rainho A, do Carmo Vale M, Estrada J, Valente R, Correia M, et al. Methadone intoxication in a child: toxic encephalopathy?. *J Child Neurol.* 2006;**21**(7):618-20. [PubMed: [16970857](#)].
9. Kornreich L, Shkalim-Zemer V, Levinsky Y, Abdallah W, Ganelin-Cohen E, Straussberg R. Acute Cerebellitis in Children: A Many-Faceted Disease. *J Child Neurol.* 2016;**31**(8):991-7. doi: [10.1177/0883073816634860](#). [PubMed: [26961264](#)].
10. Nanan R, von Stockhausen HB, Petersen B, Solymosi L, Warmuth-Metz M. Unusual pattern of leukoencephalopathy after morphine sulphate intoxication. *Neuroradiology.* 2000;**42**(11):845-8. [PubMed: [11151694](#)].
11. Keogh CF, Andrews GT, Spacey SD, Forkheim KE, Graeb DA. Neuroimaging features of heroin inhalation toxicity: "chasing the dragon". *AJR Am J Roentgenol.* 2003;**180**(3):847-50. doi: [10.2214/ajr.180.3.1800847](#). [PubMed: [12591709](#)].
12. Hagel J, Andrews G, Vertinsky T, Heran MK, Keogh C. "Chasing the dragon"-imaging of heroin inhalation leukoencephalopathy. *Can Assoc Radiol J.* 2005;**56**(4):199-203. [PubMed: [16419370](#)].