

Case Report:

Truncus Arteriosus Type 1: A Prenatal Diagnosis, Case Report, and Literature Review



Alireza Golbabaee¹ , Sara Memarian² , Mahsa Naemi³ , Azade Rastgar⁴ , Rana Karimi⁵ , Behdad Gharib² , Mohamad Taghi Majnoon^{6*}

1. Department of Perinatology and Fetal Cardiology, Shariati Hospital, Tehran University of Medical Sciences, Iran.

2. Department of Pediatrics, Children's Medical Center, Tehran University of Medical Sciences, Iran.

3. Department of Gynecology, Shariati Hospital, Tehran University of Medical Sciences, Iran.

4. Shariati Hospital, Alborz University of Medical Sciences, Karaj, Iran.

5. Department of Gynecology, Arash Hospital, Tehran University of Medical Sciences, Iran.

6. Department of Pediatrics, Children's Medical Center, Tehran University of Medical Sciences, Iran.



Citation Golbabaee AR, Memarian S, Naemi M, Rastgar A, Karimi R, Gharib B, et al. Truncus Arteriosus Type 1: A Prenatal Diagnosis, Case Report, and Literature Review. *Journal of Pediatrics Review*. 2021; 9(2):153-158. <http://dx.doi.org/10.32598/jpr.9.2.880.3>

<http://dx.doi.org/10.32598/jpr.9.2.880.3>

**Article info:**

Received: 11 Feb 2020

First Revision: 15 Mar 2020

Accepted: 11 Oct 2020

Published: 01 April 2021

Keywords:

Truncus arteriosus,
Congenital heart disease,
Fetal echocardiography

ABSTRACT

Common arterial trunk (persistent truncus arteriosus) is a rare, congenital heart anomaly and characterized by Ventricular Septal Defect (VSD), single truncal valve, and a common ventricular outflow tract. We reported a case of truncus arteriosus type 1 in the fetus of a 28 years-old G2-P1-L1 pregnant female at 24 weeks of gestational age with large sub truncal VSD, truncal overriding, and main pulmonary artery bifurcation to the right and left pulmonary arteries.

1. Context

Congenital Heart Disease (CHD) is a prevalent anomaly in newborns. The prevalence of CHD is estimated to range from 3.7 to 17.5 per 1000 live births globally (1, 2). This rate in Asia is greater than that in Europe (9.3 per 1000 live births vs. 8.2 per 1000

live births) (3). Its variations are due to maternal risk factors, i.e. different from one country to another.

Common arterial trunk (persistent truncus arteriosus) is a rare, congenital heart defect. Its characteristics are a Ventricular Septal Defect (VSD), a single truncal valve, and a common ventricular outflow tract. It is a single arterial vessel formed in the base of the heart through

* Corresponding Author:

Mohammad Taghi Majnoon, MD.

Address: Department of Pediatrics, Children's Medical Center, Tehran University of Medical Sciences, Iran.

Tel: +98 (21) 61479

E-mail: 107majnoon@gmail.com

a common truncal valve and commonly feeds to the systemic, pulmonary, and coronary arteries (4). Its incidence is 0.01 among 1000 live births (5). In this disease, the systemic venous blood and pulmonary venous blood are mixed at the VSD site, which causes desaturated blood to enter the common trunk. Common trunk usually overrides the VSD, and almost has an equal position to the Right Ventricle (RV) and the Left Ventricle (LV). In some cases, the common trunk can be predominantly originated from one of the ventricles (6, 7).

In Echocardiographic examinations, this defect can be diagnosed by visualizing the pulmonary arteries coming out from a single great artery, i.e. wider than the aorta and overriding on the interventricular septum (5). The main differential diagnosis of this anomaly is pulmonary atresia with the ventricular septal defect. This malformation can be lethal; accordingly, without surgery, death occurs within two weeks to three months after birth and the mortality rate is 85% in the first year of life (8). We presented a case of truncus arteriosus type 1, diagnosed in prenatal fetal echocardiography.

2. Case Presentation

A 28 years-old Gravid 2, Para 1, living child 1, pregnant female referred to our clinic at the 24th week of gestational age. She presented a history of a high degree of nuchal translucency in her fetus in prenatal ultrasonography. In the examinations, systematic diseases were not found. Her family history was normal. She had no history of drug usage prenatally.

In fetal echocardiography, the position and orientation of the heart were normal (levocardia & levy positions). Four-chamber view signified large sub truncal VSD and dilated truncus root (truncal overriding) (Figure 1); outlet view illustrated truncus root and main pulmonary originating from the proximal portion of truncal root (Figure 2); also, the main pulmonary artery bifurcation and division to the right and left pulmonary arteries (Figure 3). No other associated anomaly was observed. Fetal growth was normal and after the routine legal processes, the pregnancy termination was performed.

3. Discussion

Truncus arteriosus is a severe congenital cardiac malformation. For obstetric physicians and pediatric cardiologists, the prenatal diagnosis of this anomaly is a challenge.

In the study performed by Jaeggi et al., only 15% of heart defects cases could be diagnosed in the prena-

tal period (9). This rate in the study performed by Tegnaner et al. was reported as 26% by imaging 4 chambers in the fetal heart anomaly scanning (9). However, if the major vessels get visualized into the evaluation -in addition to four-chamber imaging-, this rate can surprisingly be increased to 83% (10).

In a study by Marginean et al., of 411 pregnant women, 17 (4.13%) presented truncus arteriosus; they were diagnosed at a gestational age ranging between 15 and 36 weeks. Besides, among which, only 12 had a gestational age lower than 24 weeks. They reported that among them, 9 cases had type 1, 2 cases had type 2, and in 6 cases, they could not establish a well-defined type (11).

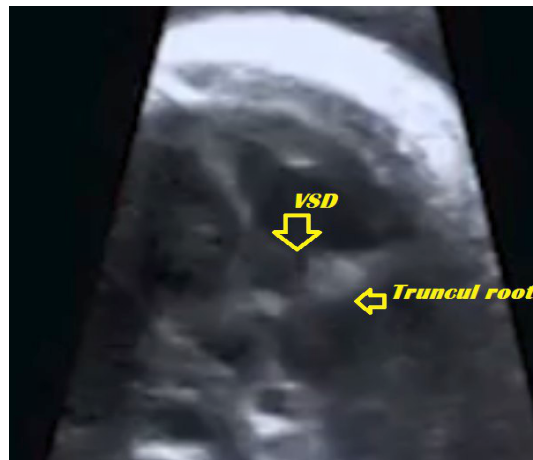This malformation is hard to diagnose with imaging technics. Moreover, as Lee et al. presented, there is confusion between truncus arteriosus diagnosis and aortic or pulmonary valve atresia. According to these scholars, among 17 cases of truncus arteriosus in prenatal diagnosing, by echocardiography or autopsy postnatally, only 12 cases were confirmed to have this anomaly (12).

Differentiating this abnormality with the tetralogy of Fallot and pulmonary atresia with VSD is important. Furthermore, 22q11.2 microdeletion (involving DiGeorge's syndrome & the related forms) presents the most associations with truncus arteriosus. The other genetic syndromes, indexed in the genesis of this cardiac anomaly are as follows: Ivemark syndrome, Fryns syndrome, Carpenter syndrome, Ellis Van Creveld syndrome, Cornelia De Lange syndrome, and Meckel-Gruber syndrome (13). Trisomies 21, 18, or 13 can be observed in 4.5% of the cases (14, 15); even the rare trisomy 8 is also detected in some cases (16, 17).

Patel et al. reported that out of 554 newborns diagnosed with truncus arteriosus, there was a coexistence of noncardiac congenital anatomic abnormalities, genetic abnormalities, and syndromes in 204 (36.8%) cases (18). Marginean C et al. argued that 5 of the 17 (29.41%) cases, have had other abnormalities and one had trisomy 18 (19).

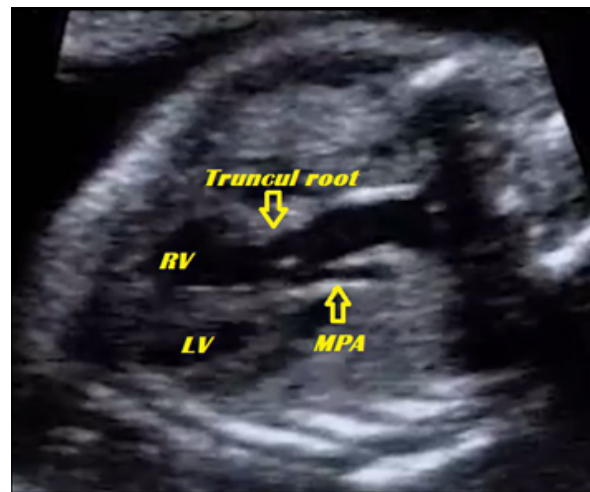
Some maternal factors involved in truncus arteriosus include the following: infections in utero, like maternal rubella; metabolic disorders, like maternal diabetes mellitus type 1 and 2; chronic maternal disease; hypertension, and obesity (20-22).

Some risk factors of gestation are so threatening and can be the cause of malformations, including the following: stress, alcohol use, cigarette smoking, abusing



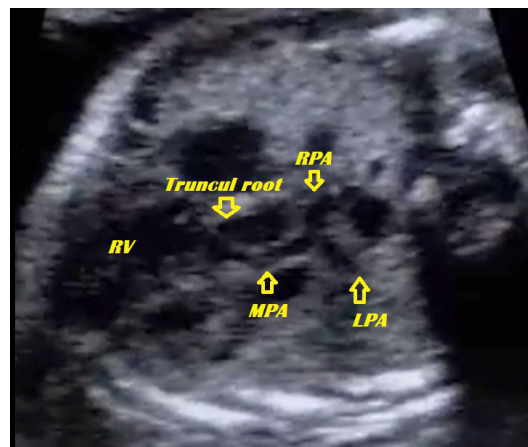
Journal of Pediatrics Review

Figure 1. Four-chamber view showing large sub truncal ventricular septal defect and dilated truncal root (truncal overriding)



Journal of Pediatrics Review

Figure 2. Outlet view showing truncal root and main pulmonary originated from proximal portion of truncal root
RV: Right Ventricle; MPA: Main Pulmonary Artery.



Journal of Pediatrics Review

Figure 3. Main pulmonary artery bifurcation and division to the right and left pulmonary arteries
RV: Right Ventricle; MPA: Main Pulmonary Artery; LPA: Left Pulmonary Artery; RPA: Right Pulmonary Artery.

coffee, retinoic acid, and valproic acid (14). Mother environment is also important and exposure to minerals, hydrocarbons, and oil derivatives before pregnancy or in the early gestation time can lead to heart defects (23). This malformation can be lethal and without surgery, death occurs between two weeks and three months after birth; the relevant mortality rate is 85% during the first year of life (8).

According to a review, post-surgical survival chance equaled 28 out of 48 cases of alive newborns with truncus arteriosus survived. Prenatal diagnosis and post-natal repair surgery can provide a 50% survival chance (24). Naimo et al. stated that in 30 years, the survival rate will reach 73.6% (25). In a study by Jacobs et al., the overall surgical mortality was reported as approximately 9.4% (26). Hussain et al. reported that infants who do not undergo surgical correction encounter a 70% first-year mortality rate and 30% of the infants die within 3 months (27). Surgical repair should be performed within the first 6 months of life to prevent severe pulmonary vasculature obstructive disease (27).

4. Conclusion

Truncus arteriosus is a rare, serious congenital heart abnormality. The good fetal echocardiography in the first trimester of gestation (from 12 weeks of embryonic development) helps an early diagnosis. This is because some types can surgically be repaired in the early stages after delivery. However, this malformation is hard to detect and the accurate diagnosis within this gestational period represents a challenge (28). Differential diagnosis is also essential, as it can be accompanied by other malformations, e.g., right side aortic arch, ASD (atrial-septal defect), coarctation of the aorta, Atrio-Ventricular Septal Defect (AVSD), mitral atresia, and the anomalies of the cardiac situs (6).

As mentioned above, this defect can have genetic causes, genetic counseling in recurrent cases, like parental consanguinity, is helpful for better prevention. Postmortem fetopathological examination will provide the most proper diagnosis in fetal death cases, i.e. not diagnosed as an antenatal congenital cardiac disease.

Ethical Considerations

Compliance with ethical guidelines

The patient's information and details have been kept confidential.

Funding

This research did not receive any grant from funding agencies in the public, commercial, or non-profit sectors.

Authors' contributions

Conceptualization: Ali Reza Golbabaeei, Azade Rastgar, Mohamad Taghi Majnoon; Methodology: Mohamad Taghi Majnoon, Rana Karimi; Investigation: Ali Reza Golbabaeei, Mohamad Taghi Majnoon, Mahsa Naemi; Writing: Behdad Gharib, Sara Memarian; Resources: Ali Reza Golbabaeei, Behdad Gharib; Supervision: Ali Reza Golbabaeei, Mohamad Taghi Majnoon.

Conflicts of interest

The authors declared no conflicts of interest.

Acknowledgements

The authors would like to thank the Department of Perinatology and Fetal Cardiology and the Department of Pediatrics of Tehran University of Medical Sciences, for their cooperation.

References

1. Kapoor R, Gupta S. Prevalence of congenital heart disease, Kanpur, India. *Indian Pediatrics*. 2008; 45(4):309-11. [PMID]
2. Bolisetty S, Daftary A, Ewald D, Knight B, Wheaton G. Congenital heart defects in Central Australia. *Medical Journal of Australia*. 2004; 180(12):614-7. [DOI:10.5694/j.1326-5377.2004.tb06122.x] [PMID]
3. van der Linde D, Konings EE, Slager MA, Witsenburg M, Helbing WA, Takkenberg JJ, et al. Birth prevalence of congenital heart disease worldwide: A systematic review and meta-analysis. *Journal of the American College of Cardiology*. 2011; 58(21):2241-7. [DOI:10.1016/j.jacc.2011.08.025] [PMID]
4. Adachi I, Ho SY, Bartelings MM, McCarthy KP, Seale A, Uemura H. Common arterial trunk with atrioventricular septal defect: New observations pertinent to repair. *The Annals of Thoracic Surgery*. 2009; 87(5):1495-9. [DOI:10.1016/j.athoracsur.2009.02.043] [PMID]
5. James DK, Steer PJ, Weiner CP, Gonik B, Robson SC. High-risk pregnancy: Management options. Cambridge: Cambridge University Press; 2017. [DOI:10.1017/9781108664677]
6. Bharati S, McAllister Jr H, Rosenquist G, Miller R, Tautoles C, Lev M. The surgical anatomy of truncus arteriosus com-

- munis. *The Journal of Thoracic and Cardiovascular Surgery*. 1974; 67(4):501. [DOI:10.1016/S0022-5223(19)40479-0]
7. Butto F, Lucas RV Jr, Edwards JE. Persistent truncus arteriosus: Pathologic anatomy in 54 cases. *Pediatric Cardiology*. 1986; 7(2):95-101. [DOI:10.1007/BF02328958] [PMID]
8. Ginelliová A, Farkaš D, Farkašová Iannaccone S. Truncus arteriosus communis with survival to the age of 46 years: Case report. *Soudní lékařství*. 2015; 60(3):37-9. [PMID]
9. Jaeggi ET, Sholler GF, Jones OD, Cooper SG. Comparative analysis of pattern, management and outcome of pre- versus postnatally diagnosed major congenital heart disease: A population-based study. *Ultrasound Obstet Gynecol*. 2001; 17(5):380-5. [DOI:10.1046/j.1469-0705.2001.00398.x] [PMID]
10. Tegnander E, Eik-Nes S, Johansen O, Linker D. Prenatal detection of heart defects at the routine fetal examination at 18 weeks in a non-selected population. *Ultrasound in Obstetrics and Gynecology*. 1995; 5(6):372-80. [DOI:10.1016/0002-9378(92)91622-H]
11. Bromley B, Estroff JA, Sanders SP, Parad R, Roberts D, Frigoletto FD, et al. Fetal echocardiography: Accuracy and limitations in a population at high and low risk for heart defects. *American Journal of Obstetrics and Gynecology*. 1992; 166(5):1473-81. [DOI:10.11152/mu-1084] [PMID]
12. Lee MY, Won HS, Lee BS, Kim EA, Kim YH, Park JJ, et al. Prenatal diagnosis of common arterial trunk: A single-center's experience. *Fetal Diagnosis and Therapy*. 2013; 34(3):152-7. [DOI:10.1159/000353771] [PMID]
13. Ta-Shma A, El-lahham N, Edvardson S, Stepensky P, Nir A, Perles Z, et al. Conotruncal malformations and absent thymus due to a deleterious NKX2-6 mutation. *Journal of Medical Genetics*. 2014; 51(4):268-70. [DOI:10.1136/jmedgenet-2013-102100] [PMID]
14. Adams MM, Mulinare J, Dooley K. Risk factors for conotruncal cardiac defects in Atlanta. *Journal of the American College of Cardiology*. 1989; 14(2):432-42. [DOI:10.1016/0735-1097(89)90199-X]
15. Harris JA, Francannet C, Pradat P, Robert E. The epidemiology of cardiovascular defects, part 2: A study based on data from three large registries of congenital malformations. *Pediatr Cardiol*. 2003; 24(3):222-35. [DOI:10.1007/s00246-002-9402-5] [PMID]
16. Bianchi DW CT, D'Alton ME, Malone F. *Fetology: Diagnosis and management of the fetal patient*. Pennsylvania: McGraw Hill Professional; 2010. <https://books.google.com/books?id=53Csy-mr1bsC&q=Fetology>
17. Sherer DM, Dalloul M, Pinard V, Sheu J, Abulafia O. Fetal trisomy 8 mosaicism associated with truncus arteriosus Type I. *Ultrasound in Obstetrics & Gynecology*. 2017; 50(4):541-2. [DOI:10.1002/uog.17411] [PMID]
18. Patel A, Costello JM, Backer CL, Pasquali SK, Hill KD, Wallace AS, et al. Prevalence of noncardiac and genetic abnormalities in neonates undergoing cardiac operations: Analysis of the society of thoracic surgeons congenital heart surgery database. *The Annals of Thoracic Surgery*. 2016; 102(5):1607-14. [DOI:10.1016/j.athoracsur.2016.04.008] [PMID] [PMCID]
19. Marginean C, Gozar L, Marginean CO, Suci H, Toganel R, Muntean I, et al. Prenatal diagnosis of the fetal common arterial trunk: A case series. *Medical Ultrasonography*. 2018; 1(1):100-4. [DOI:10.11152/mu-1084] [PMID]
20. Rubay JE, Macartney FJ, Anderson RH. A rare variant of common arterial trunk. *British Heart Journal*. 1987; 57(2):202-4. [DOI:10.1136/hrt.57.2.202] [PMID] [PMCID]
21. Zeng Z, Zhang H, Liu F, Zhang N. Current diagnosis and treatments for critical congenital heart defects. *Experimental and Therapeutic Medicine*. 2016; 11(5):1550-4. [DOI:10.3892/etm.2016.3167] [PMID] [PMCID]
22. Wu Y, Reece EA, Zhong J, Dong D, Shen WB, Harman CR, et al. Type 2 diabetes mellitus induces congenital heart defects in murine embryos by increasing oxidative stress, endoplasmic reticulum stress, and apoptosis. *American Journal of Obstetrics and Gynecology*. 2016; 215(3):366 e1- e10. [DOI:10.1016/j.ajog.2016.03.036] [PMID] [PMCID]
23. Otaigbe BE, Tabansi PN. Congenital heart disease in the Niger Delta region of Nigeria: A four-year prospective echocardiographic analysis. *Cardiovascular Journal of Africa*. 2014; 25(6):265-8. [DOI:10.5830/CVJA-2014-055] [PMID] [PMCID]
24. Abuhamad AZ, Chaoui R. *A practical guide to fetal echocardiography: Normal and abnormal hearts*. Philadelphia: Lippincott Williams & Wilkins; 2012. <https://books.google.com/books?id=6w7---gb2RIC&printsec=frontcover&dq>
25. Naimo PS, Fricke TA, Yong MS, d'Udekem Y, Kelly A, Radford DJ, et al. Outcomes of truncus arteriosus repair in children: 35 years of experience from a single institution. *Seminars in thoracic and cardiovascular surgery*. 2016; 28(2):500-11. [DOI:10.1053/j.semtcvs.2015.08.009] [PMID]
26. Jacobs JP, Mayer JE, Jr, Mavroudis C, O'Brien SM, Austin EH, 3rd, Pasquali SK, et al. The society of thoracic surgeons congenital heart surgery database: 2017 update on outcomes and quality. *The Annals of Thoracic Surgery*. 2017; 103(3):699-709. [DOI:10.1016/j.athoracsur.2017.01.004] [PMID]
27. Hussain AS, Shakir M, Ariff S, Ali R, Hassan B. Anomalous origin of the left pulmonary artery: Hemi-truncus arteriosus. *APSP Journal of case Reports*. 2017; 8(2):9. [DOI:10.21699/ajcr.v8i2.556] [PMID] [PMCID]
28. Muhler MR, Rake A, Schwabe M, Chaoui R, Helling KS, Planke C, et al. Truncus arteriosus communis in a midtrimester fetus: Comparison of prenatal ultrasound and MRI with postmortem MRI and autopsy. *European Radiology*. 2004; 14(11):2120-4. [DOI:10.1007/s00330-004-2419-9] [PMID]

This Page Intentionally Left Blank