

## Case Report:

## Potts Shunt in Children With Familial Primary Pulmonary Hypertension: A Case Report and Brief Literature Review



Mahya Mobinikhaledi<sup>1</sup>, Ali Arjmand Shabestari<sup>2</sup>, Yazdan Ghandi<sup>3\*</sup>

1. Department of Pediatrics, Faculty of Medicine, Arak University of Medical Sciences, Arak, Iran.

2. Department of Pediatrics, Amir-Kabir Hospital, School of Medicine, Arak University of Medical Sciences, Arak, Iran.

3. Department of Pediatrics Cardiology, Amir-Kabir Hospital, School of Medicine, Arak University of Medical Sciences, Arak, Iran.



**Citation** Mobinikhaledi M, Arjmand Shabestari A, Ghandi Y. Potts Shunt in Children With Familial Primary Pulmonary Hypertension: A Case Report and Brief Literature Review. *Journal of Pediatrics Review*. 2021; 9(3):247-254. <http://dx.doi.org/10.32598/jpr.9.3.913.1>

<http://dx.doi.org/10.32598/jpr.9.3.913.1>



## Article info:

Received: 30 Jun 2020

First Revision: 10 Jul 2020

Accepted: 05 Dec 2020

Published: 01 July 2021

## Keywords:

Children, Morphogenetic protein receptor type 2, Potts shunt, Pulmonary hypertension, Right ventricular failure

## ABSTRACT

**Introduction:** The primary concern about Familial Pulmonary Arterial Hypertension (FPAH) is the development of right heart failure, which ultimately leads to sudden death. Despite recent advances in pharmacological therapy, the mortality rate in children is still high, emphasizing the importance of novel treatments. Moreover, there is still no definitive treatment for children with severe pulmonary hypertension. The consequences of right heart failure led to the proposal of a surgical approach, the Potts shunt, to decompress the right ventricle, providing shunting of deoxygenated blood to lower extremities and improving overall cardiac output. This surgical technique creates an anastomosis between the left pulmonary artery and the descending aorta, providing a palliative treatment to off-load the right ventricle.

**Case Presentation:** We report an 11-year-old girl with familial pulmonary arterial hypertension and right ventricular failure who benefited from a Potts shunt with good mid-term results. The patient was diagnosed at the age of 5 when she had a history of fainting and persistent syncope. The patient was under medical treatment therapy with bosentan, sildenafil, acetylsalicylic acid, and warfarin for six years. The results of molecular genetic testing, which was confirmed with direct sequencing of the Bone Morphogenetic Protein Receptor Type 2 (*BMPR2*) gene, revealed a heterozygous pathogenic mutation. Since she was diagnosed with Pulmonary Arterial Hypertension (PAH), she lost her grandmother, an aunt, and father because of PAH. Her 14-year-old sister also had mutated the *BMPR2* gene without developing FPAH.

**Conclusions:** The Potts shunt provides an interventional step for palliation of patients with familial pulmonary hypertension and severe right heart failure refractory to medical treatment. It opens the door to the possibility of lung transplantation in the future. We did not see any complications within 6 years after placing the Potts shunt.

\* Corresponding Author:

Yazdan Ghandi, PhD.

Address: Department of Pediatrics Cardiology, Amir-Kabir Hospital, School of Medicine, Arak University of Medical Sciences, Arak, Iran.

Tel: +98 (937) 8344116

E-mail: drghandi1351@gmail.com

## 1. Introduction

**P**rimary Pulmonary Hypertension (PPH), which is caused by the obstruction of precapillary pulmonary arteries, is defined as a mean pulmonary arterial pressure >25 mm Hg at rest or >30 mm Hg during exercise [1]. The histological features reveal the proliferation of endothelial and smooth muscle cells with vascular remodeling.

As the symptoms of Pulmonary Hypertension (PHTN) develop gradually, most patients have nonspecific symptoms resulting in late diagnosis. Regarding recent reports, the average life expectancy of pediatric patients is less than a year after diagnosing the disease [2].

There is an increasing trend of mortality and morbidity in patients with serious Pulmonary Arterial Hypertension (PAH) due to congestive right heart failure. Despite recent advances in pharmacological therapy, the main concern about Familial Pulmonary Arterial Hypertension (FPAH) is the development of right heart failure, which ultimately leads to sudden death.

Pulmonary Arterial Hypertension (PAH) has insufficient intervention and dismal history. Arrhythmia and acute RV (Right Ventricle) decompensation with impairment of cardiac output are responsible for progressive RV failure and or sudden death. The measurement of RV function and off-loading its condition are respectively the major prognostic factor and the ultimate aim of all PAH treatment. Familial Primary Pulmonary Hypertension (FPPH) is an autosomal disorder mapped to a locus designated PPH1 on 2q33 with reduced penetrance and no heterogeneity sign.

Although the role of the pharmacotherapies in the survival of PAH patients has been highly noticeable, new generation treatments have been proved to promote life quality, exercise endurance, and life expectancy [3]. However, it is also undeniable that not all these patients respond to pharmacological interventions in the same way. Moreover, these interventions are not affordable and accessible to everyone, especially in developing countries [3]. Many patients who were under medical therapies develop acute symptoms of the disease. This condition highlights the importance of surgical intervention such as Atrial Septostomy (AS), lung transplantation, and Potts shunt [3]. The following methods for using drugs such as oral usage, subcutaneous injection, and inhalation are now commercially attainable, influencing one of the three major pathways involved in

pulmonary hypertension (endothelin, nitric oxide, and prostacyclin-mediated pathways).

Upon unsuccessful pharmacological therapy in children, lung transplantation has been offered. However, based on recent reports from the International Society of Heart and Lung Transplantation (ISHLT), the consequences of these surgeries were 5-year survival of 50% [2]. The surgical mortality rate is high in adults with PAH, but there is a sign of success in a surgical shunt placement (between the left pulmonary artery and descending aorta) in children. The Potts shunt is a surgical intervention that creates an anastomosis from the left pulmonary artery to the descending aorta for off-loading the right ventricle without remarkable upper body cyanosis.

To our knowledge, there have been reports of successful Potts shunts, but this is the first case of familial pulmonary hypertension who underwent the Potts shunt with desirable mid-term results. In this report, we present an 11-year-old girl with FPAH who underwent the Potts shunt when she was 5.

## 2. Case Presentation

An 11-year-old girl with FPAH was referred to our medical center. The causes of referral were exertional cyanosis and one episode of syncope. The girl was admitted with dyspnea on exertion, loss of energy, cyanosis, and substernal discomfort. On physical examination, her lungs were clear to auscultation; there was jugular vein distention to the angle of the jaw at 45° elevation with a palpable right ventricular heave. Her cardiac exam revealed a holosystolic murmur in the lower left sternal border and loud P2. On physical examination, her toenails had mild clubbing. The respiratory rate was 25 breaths/minute, the heart rate was 110 beats/minute, and the blood pressure was normal with 115/70 and 120/80 mm Hg in upper and lower extremities, respectively. Furthermore, there was not any pathological difference between upper and lower limb blood pressure. She was in functional class III at admission, and her oxygen saturation was 90% in the upper extremities and 80% in the lower extremities.

The patient was diagnosed at the age of 5 when she had a history of fainting and persistent syncope. At that time, evaluations and examinations (echocardiography, catheterization, and Tc-99m MAA lung perfusion scan) confirmed the diagnosis of FPAH. The patient underwent a surgical Potts shunt and was under medical treatment therapy with bosentan, sildenafil, ASA, and warfarin for six years without any complications. She

lost her father, aunt, and grandmother within six years due to PAH. Her 14-year-old sister also had a mutated gene without developing FPAH. The results of molecular genetic testing, which was confirmed with direct DNA sequencing of the Bone Morphogenetic Protein Receptor 2 (*BMPPR2*) gene, showed heterozygous pathogenic mutation at position c.377A>G, which encodes amino acid change of p. Asn126Ser.

A transthoracic Doppler echocardiogram showed Right Ventricular Enlargement (RVE) and Right Atrial Enlargement (RAE) with an Ejection Fraction (EF) of 65%. It showed moderate Tricuspid (TR) and Pulmonary Regurgitation (PR) with pressure gradients of 70 and 90 mm Hg, respectively. In addition, tricuspid annular plane systolic excursion, right ventricular end-diastolic diameter, and right ventricular end-systolic diameter were 10, 5.7, and 4.2 cm, respectively. Moreover, the Tricuspid Valve (TV) E/A ratio was 0.78. Additional findings included dilation of the Main Pulmonary Artery (MPA), flattening of the interventricular septum in diastole, LV deviation in systolic phase, and decreased inspiratory collapse of inferior vena cava. "D-shape" of the right ventricle with the convexity of septum towards left ventricle was visible on short-axis views. There was no intracardiac shunt.

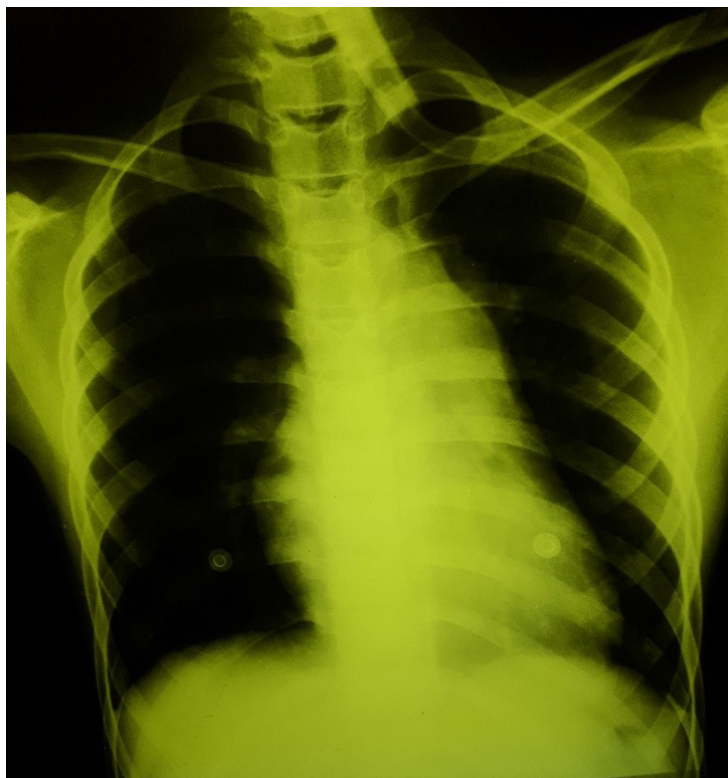Based on our echocardiography results, the patient was at a high risk of RV failure or a pulmonary hypertensive crisis. In echocardiography, the Potts shunt was seen with a desirable outcome. Chest x-ray revealed cardiomegaly, decreased Pulmonary Vascular Marking (PVM), and prominent MPA silhouette (Figure 1).

Electrocardiogram (ECG) showed sinus rhythm with RVE (tall R in V1 and right precordial leads with inverted T in V1-4) (Figures 2 and 3). Other ECG findings were T-wave inversion in leads III, aVF, and V1-4, as well as sinus tachycardia and right axis deviation.

Initial treatments and slight changes in medical therapy, including increased therapeutic dosage, were performed for the patient. Since she had syncope and right heart failure, she was referred for the examination of the Potts shunt to see whether she needs lung transplantation or angiography. Angiography can provide an opportunity for a post-dilating stent to a greater diameter.

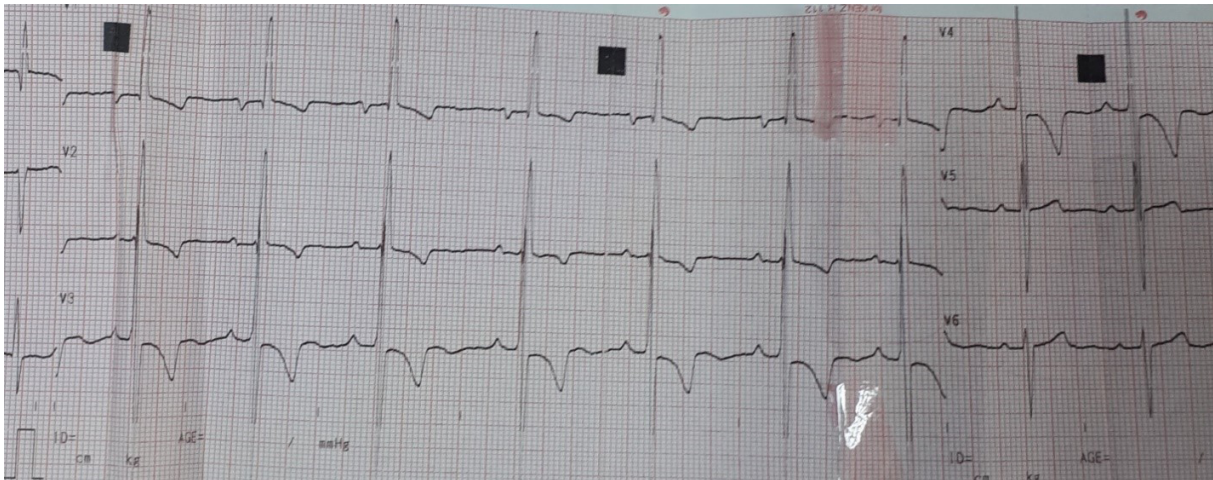
### 3. Discussion and Review of the Literature

Familial pulmonary arterial hypertension is a serious disease with the consequences of recurrent syncope and right heart dysfunction. Although there were re-



**Figure 1.** Chest X-ray revealing cardiomegaly, decreased pulmonary vascular marking, and prominent Main pulmonary artery silhouette





Journal of Pediatrics Review

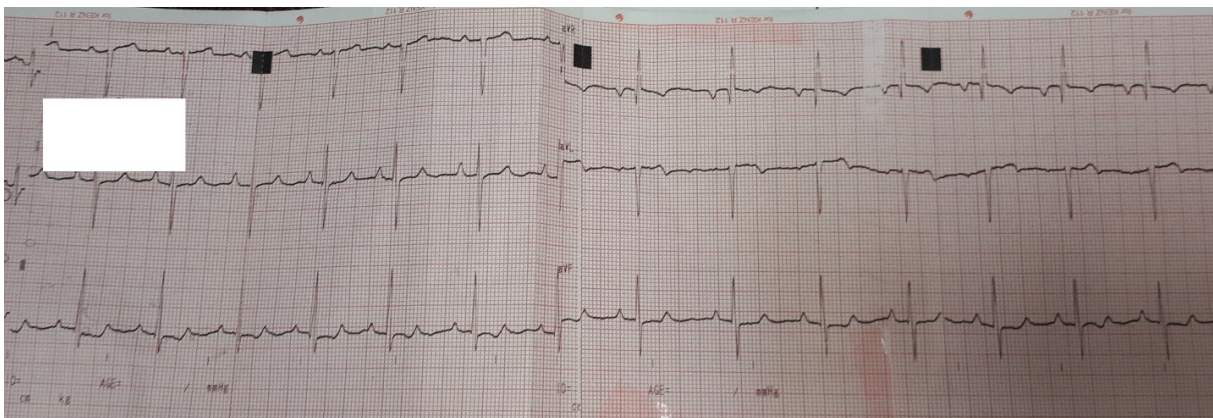
**Figure 2.** ECG showing sinus rhythm with right ventricular enlargement (tall R in V1 and right precordial leads with inverted T in V1-4)

cent advances in pharmacological therapy (e.g. endothelin receptor antagonists, prostaglandin E1, and nitric oxide), FPAH is still known for its high mortality rate due to severe RV failure.

As there was a male-to-male transmission in patients with familial pulmonary hypertension, a previous study excluded x-linkage of the gene and proved the pattern of disease as an autosomal dominant with a 2 to 1 female to male ratio [4].

To our knowledge, this is the first report of a patient with FPAH and right ventricle failure who benefited from the Potts shunt with good mid-term results. Indeed, we reported an 11-year-old girl with familial pulmonary artery hypertension who underwent a Potts shunt surgery when she was 5.

Sue Hyun Kim et al. reported a case with suprasystemic idiopathic PAH who underwent the Potts shunt with a good outcome [5]. A 4-year-old girl was admitted to their clinic with vomiting, difficulty breathing, and syncope and diagnosed with PPAH. The patient was managed with sildenafil, digoxin, and diuretics. Since the patient had a refractory right ventricular failure, she received dobutamine for eight years along with bosentan, Viagra, beraprost sodium, iloprost, digoxin, and diuretics. During eight years, she was suffered from daily left-sided chest pain and recurrent syncope, which occurred four to five times a month. Then they performed a Potts shunt on her when she was 12 to provide the possibility of lung transplantation in the future. She was discharged one month after surgery with the functional class of III. Her O<sub>2</sub> saturation in the upper and lower extremities were 98% and 74%, respectively [5].



Journal of Pediatrics Review

**Figure 3.** ECG findings considering T-wave inversion in leads III, aVF, and V1-4, sinus tachycardia and right axis deviation

Although these two cases have many similarities, such as the signs and age of their presentation, we performed a genetic evaluation for our case. Furthermore, there were more differences in the management of these two cases. The case of Sue Hyun Kim et al. underwent a Potts shunt after eight years of medical treatment while we performed a Potts shunt at the time of diagnosis and medical therapy started since then. In addition, there were improvements in the functional class of the two patients.

In 1946, Willis J. Potts devised the Potts shunt for treating cyanotic patients [6]. Necker-Enfants Hospital in Paris was the first medical center that utilized the Potts shunt to treat pulmonary arterial hypertension. The surgeons placed Potts shunts in a minority group of patients with PAH, and the short-term outcome was acceptable [7].

In previous studies, the notion of familial pulmonary hypertension occurs at an earlier age with each successive generation, raising the possibility of genetic anticipation. Genetic anticipation is a hypothesis claiming that the disease manifests at an earlier age in each successive generation and is more severe as the gene passes through successive generations. Many geneticists now believe that ascertainment bias can prove genetic anticipation [8].

JE Loyd et al. showed that the number of patients with FPPH is smaller in distant generations, although the FPPH was diagnosed in the three generations related to their cases. Yet, the idea that the severity of disease increases in a subsequent generation has remained uncertain [4].

Abnormalities of vascular and endothelial hemostasis, including imbalance of prostacyclin and thromboxane A2 and abnormal pulmonary clearance of endothelin-1, are seen in all patients with PAH. Moreover, histological lesions are present in patients who suffered from PAH [9].

Along with the progression in the usage of epoprostenol in the late 1980s and the more accessibility of sildenafil, bosentan, and iloprost, the treatment of PAH was developed noticeably in the past few years [10, 11].

While previous studies were not involved with surgical procedures, it was observed that a high group of patients received medical therapies suggested for PAH, despite the absence of controlled trials supporting their use in children. Moreover, research done by Alain Fraisse et al. [9] showed that patients, who received PAH-specific medical therapies for 2 years, showed improvement in their life quality and 6-minute walk dis-

tance. Furthermore, 73% of patients with PAH showed either improvement or no change in functional class.

Whereas patients with PAH have a dismal prognosis, the improvement in their status was promising, although they had to increase the therapeutic dosage. Comparing with the mean survival of 10 months announced by the National Institutes of Health registry in 1991 or 37% at one year and 12.5% at 2.5 years seen in a Canadian study, after the availability of PAH-specific therapies, the mean survival rates are 86% at one year and 82% at two years [12, 13]. After the treatment with bosentan, the survival rates were 88% at two years [14] and 88% at three years with epoprostenol [15] in children with idiopathic pulmonary arterial hypertension.

There was a similarity between these survival figures and those recently reported by Haworth and associates. Children with idiopathic pulmonary arterial hypertension under medical therapy with epoprostenol, sildenafil, and or bosentan had the survival rate of 86% at one year in Alain Fraisse's report and 80% at three years in Haworth's report [16].

Alain Fraisse et al. proved that dealing with novel treatments of adults with primary arterial hypertension can be a leading point to improve the management of pediatrics with PAH [9]. In other words, the idea of beginning treatment with single PAH-specific therapy and combination therapy resulted in higher disease survival in both pediatric and adult trials [16]. This finding emphasizes the need for further evaluation of the treatment of patients with pulmonary arterial hypertension, which eventually empowers physicians to make accurate decisions.

Mutations in the *BMPR2* gene have been linked to pulmonary arterial hypertension, a fetal, progressive disease of the pulmonary vascular system. Although there has been a mutation in the *BMPR2* gene in many PAH families, direct sequencing only shows a mutation in 55% of familial patients, and about 10% to 40% of cases are idiopathic pulmonary arterial hypertension [8].

Benjamin Sztrymf et al. showed that patients with *BMPR2* gene mutation predispose to a severe presentation at the diagnosis time compared with non-carriers. Furthermore, the patients with *BMPR2* gene mutation appeared to show the signs of PAH 10 years earlier than non-carriers. Knowing the mechanism of this mutation helps define a subclass of patients presenting severe signs of PAH [17]. Benjamin Sztrymf et al. also showed that the

age at which they diagnosed this disease is remarkably younger in *BMPR2* mutation carriers than non-carriers.

Patients with *BMPR2* mutation have higher mean Pulmonary Artery Pressure (PAP) and severe hemodynamic compromise at the time of diagnosis in comparison with non-carriers. Intravenous prostacyclin is more appropriate for *BMPR2* mutation carriers as the first line of therapy. In addition, the ability to undergo lung transplantation is more likely to happen in *BMPR2* mutation carriers with a remarkably shorter time to death than non-carriers. Also, death is much faster in patients with *BMPR2* mutation than non-carriers [17].

A large single-center announced that 46% of patients with PAH refused lung transplantation or died before transplantation and listing, although it was often considered a specific and promising treatment for pulmonary arterial hypertension. The decreased function is noticeable after transplantation [18, 19].

Arterial Septal Defect (ASD) creation and Potts shunt are two ways of anatomic therapy in PAH. Success in ASD creation appeared to be undesirable. Reports showed that within 24 hours of the intervention, the mortality rate is between 7% and 15% within a month [20]. Progressive RV dysfunction, hypoxia, complications of direct procedural, hemoptysis, and multiorgan failure are responsible for the death of patients with PAH. Morbidity might occur with the exposure of the cerebral circulation to hypoxemia, paradoxical emboli, and spontaneous ASD closure [21].

Catheter-based creation of a Potts shunt, previously reported in animals without PAH [22, 23], may be a logical option. Since April 2012, Transcatheter Potts Shunt (TPS) was done in 7 patients and performed in 4 by Jesse J. Esch and associates [24]. According to recent reports, TPS creation is efficient. This procedure provided an interventional step for palliation of patients with refractory PAH [24].

Indeed, Esch et al. described an innovative technique to create a TPS to bypass the risk of the surgery that was essentially needed [24]. In their research, Esch et al. placed TPS in four patients with pulmonary arterial hypertension under general anesthesia. To create the shunt, a stent should be placed between the vessels. This procedure was guided by fluoroscopy. Overall the procedure appeared successful in three patients, but one case died during the surgery because of uncontrolled hemothorax. Also, within the next few days, another patient passed away due to ventilation-associated

pneumonia. The two remaining patients, however, benefited from Potts shunt, and no complications were observed after 4 and 10 months of follow-up.

Baruteau et al. reported their experience in managing patients with PAH with both surgical anastomosis and TPS [25]. In their research, 24 patients (1.5-17 years old) with drug-refractory PAH underwent a Potts shunt (19 surgical and 5 transcatheter). Among these 24 patients, 6 (25.0%) from the surgical group showed severe complications in which 3 of them died due to low cardiac output (12.5%). There was a progressive improvement in the World Health Organization (WHO) functional class (WHO-functional class 1 or 2) in the 21 remaining patients after a median follow-up of 2.1 years which ranged from 3 months to 14.3 years. Furthermore, the mean 6-min walk distance improved. There were not any reports of syncope and deterioration of RV function. The levels of BNP (B-type natriuretic peptide) or NT-proBNP (N-terminal pro B-type natriuretic peptide) were normalized in all patients. Finally, the researchers reported that children with drug-refractory PAH who underwent Potts shunt improved in the functional class.

Since the Potts shunt reduced arterial blood oxygen saturation at the lower extremities, an arterial blood oxygen saturation gradient is created between the upper and lower extremities. The Potts shunt results in the improvement of the functions of the right side of the heart, which eventually elevates the total functional status of the patient. Furthermore, the Potts shunt lowers the suprasystemic pulmonary hypertension to the systemic level.

Based on the research accomplished by Gorbachevsky et al. [26], while a Potts shunt can dramatically minimize the chances of syncope, hypoxemia of the lower limbs is moderate and highly endurable. They also showed that a Potts shunt could decrease the right ventricle-to-left ventricle end-diastolic diameter ratio, per echocardiography, and the suprasystemic pulmonary hypertension is decreased to the systemic level, which ultimately equalizes the pressure of both ventricles [26].

It seems that Potts shunt, which creates an anastomosis between the left pulmonary artery and the descending aorta, would be an innovative procedure for the management of patients with PAH. Although this innovative approach is highly endurable and had good mid-term results, we evaluated the possibility of late complications. Likewise, in patients with Eisenmenger syndrome, chronic lower extremity cyanosis could cause renal dysfunction, erythrocytosis, hypertrophic osteoarthropathy, or gout. This condition suggests the probability of paradoxical embolism to the lower body.



The persistence of the Potts shunt's function is somehow unclear. Fortunately, we did not recognize any noticeable complications in our patient.

#### 4. Conclusion

The Potts shunt creates an anastomosis between the left pulmonary artery and the descending aorta and provides a palliative treatment to decompress the right ventricle without causing upper body cyanosis. The Potts shunt can be considered as an alternative option in the management of patients with familial pulmonary hypertension and severe right heart failure refractory to medical treatment. This procedure can open the door to the possibility of lung transplantation in the future. There were not any signs of complication in our patient within six years of follow-up.

#### Ethical Considerations

##### Compliance with ethical guidelines

The study was conducted upon agreement of the Ethics Committee of Arak University of Medical Sciences, and the informed consent of the patients is available upon request.

##### Funding

This research did not receive any grant from funding agencies in the public, commercial, or non-profit sectors.

##### Authors' contributions

Drafting of the manuscript: Ali Arjmand Shabestari and Mahya Mobinikhaledi; Conceptualization and design, critical revision of the manuscript for important intellectual content: Yazdan Ghandi and Mahya Mobinikhaledi.

##### Conflicts of interest

The authors declared no conflict of interest.

##### Acknowledgments

The authors would like to thank Arak University of Medical Science for providing medical records and questionnaire files.

#### References

1. Rubin LJ. Primary pulmonary hypertension. *Chest*. 1993; 104(1):236-50. [DOI:10.1378/chest.104.1.236] [PMID]
2. Eghtesady P. Potts shunt for children with severe pulmonary hypertension. *Operative Techniques in Thoracic and Cardiovascular Surgery*. 2015; 20(3):293-305. [DOI:10.1053/j.optechstcvs.2016.02.003]
3. Galiè N, Corris PA, Frost A, Girgis RE, Granton J, Jing ZC, et al. Updated treatment algorithm of pulmonary arterial hypertension. *Journal of the American College of Cardiology*. 2013; 62(25 Suppl):D60-72. [DOI:10.1053/j.optechstcvs.2016.02.003] [PMID]
4. Loyd JE, Primm RK, Newman JH. Familial primary pulmonary hypertension: Clinical patterns. *American Review of Respiratory Disease*. 1984; 129(1):194-7. [PMID]
5. Kim SH, Jang WS, Lim HG, Kim YJ. Potts shunt in patients with primary pulmonary hypertension. *The Korean Journal of Thoracic and Cardiovascular Surgery*. 2015; 48(1):52-4. [DOI:10.5090/kjtcs.2015.48.1.52] [PMID] [PMCID]
6. Potts WJ, Smith S, Gibson S. Anastomosis of the aorta to a pulmonary artery: Certain types in congenital heart disease. *Journal of the American Medical Association*. 1946; 132(11):627-31. [DOI:10.1001/jama.1946.02870460017005] [PMID]
7. Blanc J, Vouhé P, Bonnet D. Potts shunt in patients with pulmonary hypertension. *The New England Journal of Medicine*. 2004; 350(6):623. [DOI:10.1056/NEJM200402053500623] [PMID]
8. Aldred MA, Vijayakrishnan J, James V, Soubrier F, Gomez-Sanchez MA, Martensson G, et al. BMPR2 gene rearrangements account for a significant proportion of mutations in familial and idiopathic pulmonary arterial hypertension. *Human Mutation*. 2006; 27(2):212-3. [DOI:10.1002/humu.9398] [PMID]
9. Fraise A, Jais X, Schleich JM, di Filippo S, Maragnès P, Beghetti M, et al. Characteristics and prospective 2-year follow-up of children with pulmonary arterial hypertension in France. *Archives of Cardiovascular Diseases*. 2010; 103(2):66-74. [DOI:10.1016/j.acvd.2009.12.001] [PMID]
10. Humpl T, Reyes JT, Holtby H, Stephens D, Adatia I. Beneficial effect of oral sildenafil therapy on childhood pulmonary arterial hypertension: Twelve-month clinical trial of a single-drug, open-label, pilot study. *Circulation*. 2005; 111(24):3274-80. [DOI:10.1161/CIRCULATIONHA.104.473371] [PMID]
11. Ivy DD, Doran AK, Smith KJ, Mallory GB Jr, Beghetti M, Barst RJ, et al. Short-and long-term effects of inhaled iloprost therapy in children with pulmonary arterial hypertension. *Journal of the American College of Cardiology*. 2008; 51(2):161-9. [DOI:10.1016/j.jacc.2007.09.031] [PMID]

12. D'Alonzo GE, Barst RJ, Ayres SM, Bergofsky EH, Brundage BH, Detre KM, et al. Survival in patients with primary pulmonary hypertension. Results from a national prospective registry. *Annals of Internal Medicine*. 1991; 115(5):343-9. [DOI:10.7326/0003-4819-115-5-343] [PMID]
13. Houde C, Bohn DJ, Freedom RM, Rabinovitch M. Profile of paediatric patients with pulmonary hypertension judged by responsiveness to vasodilators. *British Heart Journal*. 1993; 70(5):461-8. [DOI:10.1136/hrt.70.5.461] [PMID]
14. Rosenzweig EB, Ivy DD, Widlitz A, Doran A, Claussen LR, Yung D, et al. Effects of long-term bosentan in children with pulmonary arterial hypertension. *Journal of the American College of Cardiology*. 2005; 46(4):697-704. [DOI:10.1016/j.jacc.2005.01.066] [PMID]
15. Alonso EM, Neighbors K, Mattson C, Sweet E, Ruch-Ross H, Berry C, et al. Functional outcomes of pediatric liver transplantation. *Journal of Pediatric Gastroenterology and Nutrition*. 2003; 37(2):155-60. [DOI:10.1097/00005176-200308000-00014] [PMID]
16. Haworth SG, Hislop AA. Treatment and survival in children with pulmonary arterial hypertension: The UK Pulmonary Hypertension Service for Children 2001-2006. *Heart*. 2009; 95(4):312-7. [DOI:10.1097/00005176-200308000-00014] [PMID]
17. Sztrymf B, Coulet F, Girerd B, Yaici A, Jais X, Sitbon O, et al. Clinical outcomes of pulmonary arterial hypertension in carriers of BMPR2 mutation. *American Journal of Respiratory and Critical Care Medicine*. 2008; 177(12):1377-83. [DOI:10.1164/rccm.200712-1807OC] [PMID]
18. Chen H, Shiboski SC, Golden JA, Gould MK, Hays SR, Hoopes CW, et al. Impact of the lung allocation score on lung transplantation for pulmonary arterial hypertension. *American Journal of Respiratory and Critical Care Medicine*. 2009; 180(5):468-74. [DOI:10.1164/rccm.200810-1603OC] [PMID]
19. de Perrot M, Granton JT, McRae K, Pierre AF, Singer LG, Waddell TK, et al. Outcome of patients with pulmonary arterial hypertension referred for lung transplantation: A 14-year single-center experience. *The Journal of Thoracic and Cardiovascular Surgery*. 2012; 143(4):910-8. [DOI:10.1016/j.jtcvs.2011.08.055] [PMID]
20. Keogh AM, Mayer E, Benza RL, Corris P, Darteville PG, Frost AE, et al. Interventional and surgical modalities of treatment in pulmonary hypertension. *Journal of the American College of Cardiology*. 2009; 54(1 Suppl):S67-77. [DOI:10.1016/j.jtcvs.2011.08.055] [PMID]
21. Law MA, Grifka RG, Mullins CE, Nihill MR. Atrial septostomy improves survival in select patients with pulmonary hypertension. *American Heart Journal*. 2007; 153(5):779-84. [DOI:10.1016/j.ahj.2007.02.019] [PMID]
22. Levi DS, Danon S, Gordon B, Viridone N, Vinuela Jr F, Shah S, et al. Creation of transcatheter aortopulmonary and cavopulmonary shunts using magnetic catheters: Feasibility study in swine. *Pediatric Cardiology*. 2009; 30(4):397-403. [DOI:10.1007/s00246-009-9422-5] [PMID]
23. Sabi TM, Schmitt B, Sigler M, Zanjani KS, Ovroutski S, Peters B, et al. Transcatheter creation of an aortopulmonary shunt in an animal model. *Catheterization and Cardiovascular Interventions*. 2010; 75(4):563-9. [DOI:10.1002/ccd.22150] [PMID]
24. Esch JJ, Shah PB, Cockrill BA, Farber HW, Landzberg MJ, Mehra MR, et al. Transcatheter Potts shunt creation in patients with severe pulmonary arterial hypertension: Initial clinical experience. *The Journal of Heart and Lung Transplantation*. 2013; 32(4):381-7. [DOI:10.1016/j.healun.2013.01.1049] [PMID]
25. Baruteau AE, Belli E, Boudjemline Y, Laux D, Lévy M, Simonneau G, et al. Palliative Potts shunt for the treatment of children with drug-refractory pulmonary arterial hypertension: Updated data from the first 24 patients. *European Journal of Cardio-Thoracic Surgery*. 2015; 47(3):e105-10. [DOI:10.1016/j.healun.2013.01.1049] [PMID]
26. Gorbachevsky SV, Shmalts AA, Barishnikova IV, Zaets SB. Potts shunt in children with pulmonary arterial hypertension: Institutional experience. *Interactive Cardiovascular and Thoracic Surgery*. 2017; 25(4):595-9. [DOI:10.1093/icvts/ivx209] [PMID]