



Tubularized incised plate urethroplasty with or without stent in Hypospadias repair: a systematic review and meta-analysis

Seyed Abdollah Mousavi^{1*}

Mohsen Aarabi²

¹Department of Pediatric Surgery, Faculty of Medicine, Mazandaran University of Medical Sciences, Sari, Iran

²Health Sciences Research Center, Mazandaran University of Medical Sciences, Sari, Iran

ARTICLE INFO

Article type:

Review Article

Article history:

Received: 8 April 2014

Revised: 11 May 2014

Accepted: 2 June 2014

Keywords:

Hypospadias, Stents,
Urethroplasty

<http://jpr.mazums.ac.ir>

ABSTRACT

Numerous methods for repair of hypospadias have been introduced. The technique of Tubularized Incised Plate urethroplasty has gained widespread acceptance. In the classical method of Tubularized Incised Plate urethroplasty, to divert urine flow and preventing urethral stenosis, a stent was used, but its necessity is questionable for some surgeons.

In this paper we systematically compared the results of operations in different studies. Searching the databases such as PubMed, SCOPUS, and Google Scholar was done and articles found from January 1994 to September 2013 were included. Then articles about the impact of use or non-use of urinary catheters on surgical outcomes were analyzed.

By reviewing 168 studies related to repair of hypospadias with TIP, we selected 11 studies that met our inclusion criteria which did not use a stent. A total of 708 children had urethroplasty using the TIP method without stent. The overall complication rate such as meatal stenosis and fistula compared with stents was not significant.

It could tell us that at least in some cases especially in distal types, use of stent can be avoided, because its least benefit would be reduction of bladder spasm and urinary tract infections.

Introduction

Hypospadias is one of the most common congenital abnormalities in boys characterized by a meatus that opens into the ventral surface of penis. Hypospadias classification is according to meatal location (anterior, middle and posterior). The

incidence has been calculated as 1 in 300 live male births.¹ Up to now, there are various methods and innovations to repair this abnormality, but almost in all cases, fistula as the most common complication and then dehiscence are the side effects that surgeons

*Corresponding Author: Seyed Abdollah Mousavi, Associated Professor of Pediatric Surgery

Mailing Address: Department of Pediatric Surgery, Bou Ali Sina Hospital, Pasdaran Boulevard, Sari, Iran.

Tel: +98 151 2233010-16

Fax: +98 151 2235358

Email: Dr.a.mosavi@gmail.com

are worried about them. The other main complications are meatal stenosis, residual chordee and diverticulum.¹

In 1994 Warren Snodgrass had described a procedure using a Tubularized incised plate (TIP) and its excellent results. In this method, making a longitudinal incision on the urethral plate (UP) with tubularization to make a neourethra and putting a flap on it can minimize the rate of complication. The most important note in this technique is creating a relaxing incision in the UP and using protective dartos flap to cover the neourethra.^{2,3}

Although at first this method was used in cases of distal hypospadias, several years later, published articles on a variety of proximal forms were also demonstrated its success.⁴⁻⁶ This technique quickly became widespread and has been popular during the following years in the world.

In the classical method of TIP, to divert urine flow and preventing urethral orifice stenosis, a stent was used, but its necessity is questionable for some surgeons.⁷⁻¹¹

There is a point here that in order to avoid possible complications, especially meatal stenosis, is urinary catheter insertion required? This study aimed to determine the prevalence of hypospadias complications following the TIP method with or without using stent. In this paper we systematically compare the results of operations in different studies.

Method of Literature Review

A systematic review was conducted on published papers which studied the complications of these two surgical approaches. Searching the databases including PubMed, SCOPUS and Google Scholar was done from January 1994; the time of inventing this method to September

2013 by using MeSH Headings including: Snodgrass, hypospadias, stent, Tubularized incised plate urethroplasty and complication. All abstract and full text English-language articles were studied. Then articles about the impact of use or non-use of urinary catheters on surgical outcomes were analyzed and other publications were excluded. In cases that the urinary catheters were removed within 24 hours, it was considered as without using catheter. In this review, all original articles in which the stent was not used compared to the studies using stent were selected. Stent group included a systematic review performed by Braga et al.¹² All types of hypospadias, including proximal, middle and distal were included in our study. Studied complications included all cases of fistula, meatal stenosis, extravasation, urinary retention, and dehiscence.

Studies that included patients with glanular type, catheters that removed within 24 hours, types of reoperation and operation in adult ages were excluded. Also, animal studies, patients in puberty or sample size less than or equal to 5 cases were not included. Data on all cases of the two groups related to surgery, average age, type of hypospadias and number of complicated cases (based on type of complication) were extracted from all the papers.

Data analysis was performed using trial version of Stats Direct Software and evaluation of heterogeneity was done by I^2 and Cochrane Q statistics (with significance of $P < 0.1$). Due to the lack of heterogeneity in the data, for meta-analysis and estimating the overall incidence of complications for total data from all studies, the random effects model was used.

Descriptive statistics were performed using SPSS V. 15. Complication rates between various series were compared using two-sided χ^2 -test.

Table 1: Studies comparing the Snodgrass repair with and without usage of urethral stent

Author (Date)	Type	Technique (N)	Meatal Stenosis (%)	Fistula	Urinary Retention	Extravasation	Bladder Spasm
Elsherbiny ¹⁶ (2003)	D	S (35)	1 (3%)	2 (6%)	-	-	3 (8%)
		N.S (29)	1 (3%)	5 (17%)	7 (24%)	5 (17%)	-
Aslan ¹⁵ (2007)	D	S (29)	-	2 (6.9%)	-	-	-
		N.S (99)	3 (3%)	7 (7%)	-	-	-
Radwan ¹³ (2012)	D	S (129)	11 (8.5%)	11 (8.5%)	-	-	43 (33%)
		N.S (63)	3 (2.3%)	3 (2.3%)	-	-	-
Xu ¹⁴ (2013)	D-M	S (103)	3 (2.9%)	6 (5.8%)	-	-	11 (10.7%)
		N. S (151)	5(3.3%)	8 (5.3%)	6 (4%)	2 (1.3%)	-
Total		S (296)	15 (5%)	21 (7.1%)	-	-	57 (19.2%)
		N.S (342)	12 (3.5%)	23 (6.7%)	13 (3.8%)	7 (2%)	-

D= distal shaft, M= mid shaft, S= stent, NS= no stent

Results

By reviewing 168 studies related to repair of hypospadias with TIP, we found 29 papers with regard to catheterization and meatal stenosis. After removing case report and animal studies,

11 studies that met our inclusion criteria and not used a stent were selected. Although in some cases the stent were used in this study, but the subjects were excluded from the general population due to short time usage of stent or reoperation.^{8, 13-16}

A total of 708 children had urethroplasty using the TIP method without stent. The mean age of the patients was 35 months. Six hundred and four cases were distal hypospadias and 79 were mid shaft. Mean duration of follow-up was 17.9 months (6-24

months). In addition, in four of these studies, the results of two urethroplasty techniques with and without stent were compared and shown in Table 1.

Discussion

Animal studies

Hafez induced hypospadias in 13 rabbits.¹⁷ Then urethroplasty without the use of stent was done by TIP method. Urethrography and biopsy were performed at second day, second week, fifth and sixth week and at 12 week. No complications were observed. Histological assessment determined that urothelium fully restored as well in the second week in the absence of the stent. Therefore, it can be concluded that the stent is not necessary for repair.

Table 2: Studies comparing the Stent-free tubularized incised plate repair of hypospadias

Author (Date)	Number	Type(N)	Mean Age(month)	Fistula N (%)	Meatal Stenosis N (%)	Urinary Retention N (%)	Dehiscence N (%)	Extravasation N (%)	Follow up duration (month)
Steckler ³⁹ (1997)	31	D(31)	12	0	0	0	0	0	-
Smith ⁴⁰ (2001)	52	D,M(45,7)	22.9	0	0	0	0	0	21
El-sherbiny ¹⁶ (2003)	29	D(29)	72	5(17%)	6(20%)	7(24%)	0	5(17%)	6
Leclair ²⁵ (2004)	126	D,M	15.7	9(5.6%)	4(2.5%)	3(2.5%)	6(4.4%)	0	12.4
Aslan ¹⁵ (2006)	99	D(99)	33.4	7(7%)	3(3%)	0	0	0	22.3
Almodhen ⁹ (2008)	32	D-M, P(26,6)	18	0	0	0	0	1(1.3%)	9
Turial ¹⁰ (2011)	41	D,M(25,16)	22	2(4.8%)	1(2.4%)	0	0	0	22
El-sherbiny ⁷ (2004)	39	D(39)	84	4(10%)	2(5%)	0	1(3%)	0	10
Ritch ⁴² (2010)	45	D(45)	-	3(6.7%)	0	0	0	0	12
Radwan ¹³ (2012)	63	D(63)	21.5	3(2.3%)	8(12.7%)	0	0	0	21.5
XU ¹⁴ (2013)	151	D,M(102,49)	54	8(5.3%)	5 (3.3%)	6 (4%)	0	2 (1.3%)	24

D= distal shaft, M= mid shaft, P= proximal shaft

Lopez, in a study on a number of pigs concluded that re-epithelialization is completed on the fifth day.¹⁸ On the other hand, Eassa in an article published in 2011, in an animal model showed that using stent for 7 days after surgery adds only 2 mm to the surface of urethral plate that was not statistically significant.¹⁹

Human studies

Buson in 1994 presented the first report about the lack of using stent in hypospadias repair by Mathieu method, and emphasized on using stent for 2-5 days due to high rate of complications of urinary retention and fistula.⁸ The complication rate in the non- stent group was 18.9% vs. 4.6% in the stent group. However, a similar study on 222 patients by Hakim et al concluded that placement of stent

or leaving it had no effect on rate of complication.¹¹

Overall complication rate

Braga et al (RA)¹² in a review article written about the results of hypospadias repair using the TIP analyzed the side effects of surgery. They reviewed 66 studies with a population of 4554. Although all cases in Braga's study had distal hypospadias, in our study the majority of patients had distal type as well. Also, they excluded adult studies; reoperation and articles reported very high complications due to performing the surgery by less-experienced surgeons. In most cases of surgeries urethral stent was used. Finally, with regard to the mentioned above considerations, the total complication rate were determined 6.5% (mean = 7.3%). They also concluded in a study with a sample size more than 30 patients that more experience of surgeons resulted in a less chance of complications. This subject has shown more prominent in the experience of Snodgrass series as the inventor of this technique. As in a review article and evaluation of 10 studies with participation of 750 people, the incidence of complications was 7%. Although, the incidence of surgical complications when performed by himself has ranged from 0 to 4%.^{2, 3, 20-23}

In our study, by reviewing 11 studies and 708 patients, the overall incidence of complications was determined 14.26%. Since the most important complications of hypospadias repair are fistula and meatal stenosis, without considering other complications, the total complication rate was 9.03%. (95%CI: 4.77 to 14.47) (Table 2).

Although like Braga et al¹² study, we did not remove the studies with too much side effects, if we exit the study with the largest effect from the reviews, the prevalence of total complications will decrease to

8.9%(95%CI: 3.9 to 15.7), and as a result the overall complication rate compared with stents will not be significant ($P>0.05$).

Fistula rate

In article by Braga et al¹² repairing of urethra by distal TIP method with stent, the prevalence of fistula has ranged from 0-16% (Mean = 5.9%). They concluded that several factors can affect the fistula such as; surgical techniques, dealing with the delicate tissue, age, type of hypospadias, proper coverage of hypospadias and proper repair of the skin.

This review found five studies in which the prepuce was saved and the prevalence of fistula increased to 14%.

Perlmutter et al showed that the rate of complication in children younger than six months is less than older ones.²¹

Our review of 11 studies also showed that the mean prevalence of fistula is 5.6% (95%CI: 3.3 to 8.5) when using TIP method without stents. Therefore, the prevalence of fistula compared with surgery using stents in our review was similar to Braga et al. literature review study (mean=5.5%, 95%CI: 1.9 to 10.) ($P>0.05$).¹²

In a study by Radwan on 192 patients, it was confirmed that what plays an important role on creating fistula is the correct diversion of urine flow through the supra pubic catheter.¹

In another study, Elbakry showed that repeated dilation and meatal stenosis had more important role for prevention of fistula, because placement of stent without dilatation, the prevalence of fistula reaches 31%, while with dilatation, it will be 3%.²²

Meatal stenosis

Although Snodgrass with repeated dilatation and final evaluation with ureteroscopy reported that the prevalence of stenosis was less than one percent²³, according to the Braga et al study¹², the repair of distal hypospadias with the TIP method without

stent, the prevalence of meatal stenosis was determined from 0-17% (mean=2.1%). In some of these studies, the prevalence of meatal stenosis was high from 6-20% which could be due to inappropriate technique and continuing the incision up to the tip of glans.²⁴⁻³¹

In this study, by evaluating 11 articles and 708 patients who underwent TIP urethroplasty without stent we found that the prevalence of meatal stenosis varied from 0-20% (mean = 4.1%)(95%CI: 1.8 to 6). Thus, likewise, the prevalence of meatal stenosis was not significant compared to patients with stent surgery in Braga et al study ($P>0.05$).

As noted earlier, meatal stenosis due to creating a resistance against the flow of urine can increase the prevalence of fistula. So, to avoid both complications, some recommend repeated meatus dilatation.^{22, 23} In a study, Snodgrass performed surgery on 72 patients. Then postoperative dilatation was performed for all of the patients. After a year, they were evaluated by uroflowmetry for stenosis. During calibration and uroflowmetry was proved that no narrowing of the lumen occurred.²³

On the other hand, in the study by Lorenzo³², 134 patients with proximal and distal hypospadias were divided into two groups. The first group had a regular urethral dilatation and the second group did not. Degree of Meatal stenosis was seen only in 0.7% of cases that was equal in both groups. Finally, the researcher suggested performing uroflowmetry for all cases 6 months after surgery to treat asymptomatic stenosis.

Meatal stenosis and follow up with Uroflowmetry

According to some surgeons, stent placement alone is not a factor to prevent a stenosis and dilatation should be performed frequently. Elbakry^{22,23} divided 64 patients into two groups. All patients had a stent for 10-12

days. The first group was 38 patients that had daily dilatation for 12 weeks but the second group did not. In total, 9% of cases had complication. Three percent was in group with dilatation and 31% in group without dilatation. In second group, six patients developed a fistula and two patients were involved with urethral stenosis. Four patients who had fistulas also had meatal stenosis. Thus, despite stent placement to prevent meatal stenosis and subsequent increasing the chance of fistula, repeated dilatation was recommended.

Asymptomatic stenosis is cases that may not be included as side effects. Marte³⁴ during a study on 21 patients who apparently had no problem found 3 meatal stenosis following uroflowmetry.

In another study³⁵, Tuygun et al. carried out serial uroflowmetry in 70 patients aged 30 months after surgery. Among them 10 showed stenosis, although they were clinically asymptomatic. The mean duration of showing the stenosis was 10.5 months after surgery. So that, it is recommended to assess stenosis in all cases.

On the other hand, Holmdahl³⁶ and colleagues in a study on 126 children who underwent surgery performed uroflowmetry in 68 patients two months after surgery and 12 months for the rest of the patients. Initial uroflowmetry showed 49% of patients with distal hypospadias and 87% of patients with proximal type had low flow rate, but in delayed uroflowmetry, only 10% showed stenosis. Therefore, in patients who do not need initial uroflowmetry and in symptomatic cases or proximal type, uroflowmetry is better doing.

Also, Andersson et al evaluated 48 patients who had uroflowmetry one year and seven years after urethroplasty. He showed that in many of the patients urinary flow will return

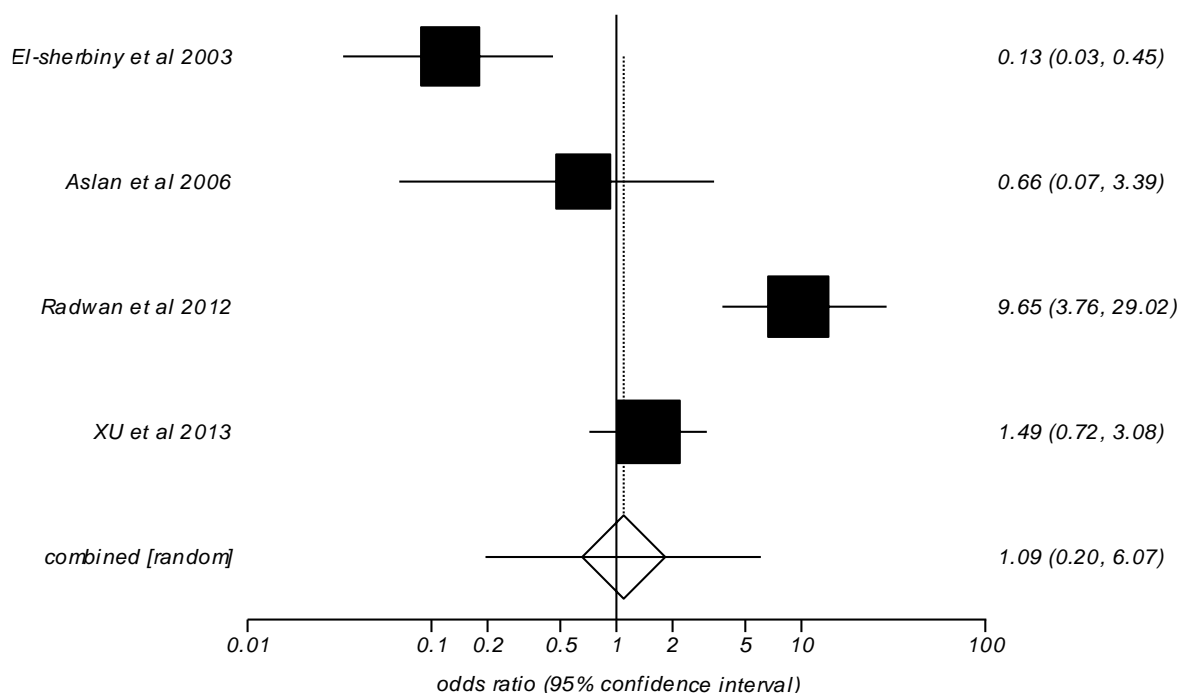


Figure 1. Odds ratio meta-analysis plot and random effects in studies of the Snodgrass repair with and without usage of urethral stent

to normal over the time.³⁷ Eassa also found similar results.¹⁹ Although some surgeons believe that patients need to longer follow-up.³⁴⁻³⁸

Comparative analysis between studies with and without use of stent urethroplasty

In this review we found four studies by TIP method that compared using or not using the stent. They are illustrated in table.1.

According to the meta analysis results, use of stent is associated with more complications, but the results is not statistically significant [OR=1.1 (CI 95%:0.2 to 6.1), (P>0.05).

The prevalence of fistula as a side effect was not affected by presenting or not of stent [OR=1.05 (CI 95%:0.50 to 2.1),(P>0.05). Similar result was obtained for meatal stenosis [OR=1.2 (95% CI: 0.5 to 2.7)].

In a study by El-sherbiny¹⁶ 64 children with distal hypospadias underwent surgery by two different techniques, stent and stent-free. The rate of postoperative complications, including

painful voiding, urinary retention extravasation and meatal stenosis was higher in non- stent group. Considering the above results, to reduce complications, it is better if the stent stays for a week after surgery.

Aslan in a study examined the role of stent on 183 children with distal shaft hypospadias repair at two-center.¹⁵ Catheter was removed before 24 hours in one group (99 patients) and in second group it was remained for 7-14 days after surgery (29 patients). During follow-up, it was cleared that the duration of catheter insertion had no effect on developing complications. This is also not related to the type of hypospadias and toilet-training of children. The rate of complication in group I and II was 11.1% (7 fistula and 3stenosis), and 13.8% (2 fistula and one dehiscence), respectively.

Radwan¹³ in a study divided 192 patients into three groups. Urethral stent was used for first group. The second group had suprapubic

catheter and in the third group, a narrow anterior urethral stent was used in addition to suprapubic catheter. The prevalence of bladder spasm in the first group was 33% and in the rest it was zero. 12.7% had developed fistula, and the rate of fistula was reported 2.3% in the other two groups. Meatal stenosis in second group that had not used the stent was 12.7%, while in the other two groups it was 2.3%. They concluded that intra-luminal stent could prevent meatal stenosis.

XU¹⁴ in a study on 254 children with distal and middle hypospadias, did not use stent in 151 of them. Bladder spasms and urinary tract infections were higher in the stent group. Urinary retention in the stent group was 4%, while it was not statistically significant in other group. (Figure 1)

Leclair In 2004 used the TIP technique without stent in 126 patients with middle and distal hypospadias. Complications included 5.6% fistula and 2.5% meatal stenosis. Suprapubic catheter was used in 2.5% of patients due to urinary retention.²⁵

Almodhen⁹ operated 32 patients with proximal, middle and distal hypospadias without stent. Urinary extravasation was observed in one case (3.1%) and the problem was resolved with the insertion of the catheter for 5 days. No other complications were observed, and all the patients had excellent cosmetic.

They claimed that leaving the stent, there is no need to prescribe antibiotics and anticholinergics. Steckler also in distal hypospadias repair by Thiersch-Duplay method that modified by TIP found similar results.³⁹

Smith in 2001 in a study of 52 children with different types of hypospadias (MS - DS) repaired the defect with modified TIP procedure. In this approach, the cut was deep up but was not drawn until the tip of Glans.

Stent was not used in these patients and the rate of complications was zero.⁴⁰

Conclusion

As can be seen in almost all of the studies, related to use of stent, in urethroplasty, a catheter was used for proper calibration. The difference is that some researchers believe in using it and then removing it within 24 hours.^{42, 10} Other group keep it in place for a longer time.^{13, 15, 16, 33, 41}

Comparing the two approaches in a large volume with acceptable results can be very difficult and in this regard we were able to compare the results with the literature review. Clearly, making conclusion can be difficult due to lack of homogeneity and different results reported by surgeons. But it could tell us that at least in some cases especially in distal types, use of stent can be avoided, because its least benefit would be reduction of bladder spasm and urinary tract infections. Further case control studies with adequate sample size, will probably clear the possible doubts.

Conflict of Interest

None declared.

Funding/Support

None declared.

Acknowledgements

The authors would like to thank soheila shahmohammadi for her cooperation in writing this text.

References

1. Borer JG, Retik AB. Hypospadias. In: Wein AJ, ed. Campbell-Walsh Urology. 9th ed. Philadelphia, Saunders Elsevier; 2007: chap 125.

2. Snodgrass W. Tubularized, incised plate urethroplasty for distal hypospadias. *J Urol* 1994; 151(2): 464-5.
3. Snodgrass WT, Bush N, Cost N. Tubularized incised plate hypospadias repair for distal hypospadias. *J PediatrUrol* 2010; 6(4):408-13.
4. Snodgrass W, Koyle M, Manzoni G, Hurwitz R, Caldamone A, Ehrlich R. Tubularized incised plate hypospadias repair for proximal hypospadias. *J Urol*. 1998; 159(6): 2129-31.
5. Mousavi SA, Mohammadjafari H. Circumcision with the plastibell device in hooded prepuce or glanular hypospadias. *Adv Urol*. 2009;864816.
6. Mousavi SA. Use of tubularized incised plate urethroplasty for secondary hypospadias repair or repair in circumcised patients. *Int Braz J Urol* 2008; 34(5): 609-14.
7. El-Sherbiny MT, Hafez AT, Dawaba MS, Shorrab AA, BazeedMA. Comprehensive analysis of tubularized incised-plate urethroplasty in primary and re-operative hypospadias. *BJU Int*. 2004; 93(7): 1057-61.
8. Buson H, Smiley D, Reinberg Y, Gonzalez R. Distal hypospadias repair without stents: is it better? *J Urol*. 1994; 151(4): 1059-60.
9. Almodhen F, Alzahrani A, Jednak R, Capolicchio JP, El Sherbiny MT. Nonstented tubularized incised plate urethroplasty with Y-to-I spongioplasty in non-toilet trained children. *Can Urol Assoc J*. 2008; 2(2): 110-4.
10. Turial S, Enders J, Engel V, Schier F. Stent-free tubularized incised plate (TIP) repair of distal and mid-shaft hypospadias irrespective of age. *Eur J Pediatr Surg*. 2011; 21(3):168-70.
11. Hakim SP, Merguerian A, Rabinowitz R, Shortliffe LD, McKenna PH. Outcome analysis of the modified Mathieu hypospadias repair: comparison of stented and unstented repairs. *J Urol* 1996; 156 (2 Pt 2): 836-8.
12. Braga LH, Lorenzo AJ, Salle JL. Tubularized incised plate urethroplasty for distal hypospadias: A literature review. *Indian J Urol*. 2008; 24(2): 219-225.
13. Radwan M, Soliman MG, Tawfik A, Abo-Elenen M, El-Benday M. Does the type of urinary diversion affect the result of distal hypospadias repair? A prospective randomized trial. *Ther Adv Urol*. 2012; 4(4): 161-5.
14. Xu N, Xue XY, Wei Y, Li XD, Zheng QS, Jiang T, et al. Outcome analysis of tubularized incised plate repair in hypospadias: is a catheter necessary? *Urol Int*. 2013; 90(3): 354-7.
15. Aslan AR, Yücebaş E, Tekin A, Sengör F, Kogan BA. Short-term catheterization after TIP repair in distal hypospadias: who are the best candidates? *Pediatr Surg Int*. 2007; 23(3): 265-9.
16. El-Sherbiny MT. Tubularized incised plate repair of distal hypospadias in toilet-trained children: should a stent be left? *BJU Int*. 2003; 92(9): 1003-5.
17. Hafez AT, Herz D, Bağli D, Smith CR, McLorie G, Khoury AE. Healing of unstented tubularized incised plate urethroplasty: an experimental study in a rabbit model. *BJU Int*. 2003 Jan;91(1):84-8.
18. Lopes JF, Schned A, Ellsworth PI, Cendron M. Histological analysis of urethral healing after tubularized incised plate urethroplasty. *J Urol*. 2001; 166(3): 1014-7.
19. Eassa W, Brzezinski A, Capolicchio JP, Jednak R, El-Sherbiny M. How do asymptomatic toilet-trained children void following tubularized incised-plate hypospadias repair? *Can Urol Assoc J*. 2012; 6(4):238-42.
20. Snodgrass W, Koyle M, Manzoni G, Hurwitz R, Caldamone A, Ehrlich R. Tubularized incised plate hypospadias repair: Results of a multicenter experience. *J Urol* 1996;156 (2 Pt 2): 839-41.
21. Perlmutter AE, Morabito R, Tarry WF. Impact of patient age on distal hypospadias repair: A surgical perspective. *Urology* 2006; 68(3): 648-51.
22. Elbakry A. Tubularized-incised urethral plate urethroplasty: is regular dilatation necessary for success? *BJU Int* 1999; 84(6): 683-8.
23. Snodgrass W. Does tubularized incised plate hypospadias repair create neourethral strictures? *J Urol* 1999; 162(3 Pt 2): 1159-61.

24. Moradi M, Moradi A, Ghaderpanah F. Comparison of Snodgrass and Mathieu surgical techniques in anterior distal shaft hypospadias repair. *Urol J* 2005; 2(1): 28-30.
25. Leclair MD, Camby C, Battisti S, Renaud G, Plattner V, Heloury Y. Unstented tubularized incised plate urethroplasty combined with foreskin reconstruction for distal hypospadias. *Eur Urol*. 2004; 46(4): 526-30.
26. Stehr M, Lehner M, Schuster T, Heinrich M, Dietz HG. Tubularized incised plate (TIP) urethroplasty (Snodgrass) in primary hypospadias repair. *Eur J Pediatr Surg* 2005; 15(6): 420-4.
27. Tonvichien L, Niramis R. Tubularized, incised plate urethroplasty in hypospadias repair: Experience at Queen Sirikit National Institute of Child Health. *J Med Assoc Thailand* 2003; 86(Suppl3): S522-30.
28. Barrack SM, Hamdun SH. Tubularized, incised plate urethroplasty for distal hypospadias. *East Afr Med J* 2001; 78(6): 327-9.
29. Mustafa M. The concept of tubularized incised plate hypospadias repair for different types of hypospadias. *Int Urol Nephrol* 2005; 37(1): 89-91.
30. Soygur T, Arikan N, Zumrutbas AE, Gulpinar O. Snodgrass hypospadias repair with ventral based dartos flap in combination with mucosal collars. *Eur Urol* 2005; 47(6): 879-84.
31. Al-Hunayan AA, Kehinde EO, Elsalam MA, Al-Mukhtar RS. Tubularized incised plate urethroplasty: Modification and outcome. *Int Urol Nephrol* 2003; 35(1): 47-52.
32. Lorenzo AJ, Snodgrass WT. Regular dilatation is unnecessary after tubularized incised-plate hypospadias repair. *BJU Int* 2002; 89(1): 94-7.
33. Elbakry A. Further experience with the Tubularized-incised urethral plate technique for hypospadias repair. *BJU Int* 2002; 89(3): 291-4.
34. Marte A, Di Iorio G, De Pasquale M, Cotrufo AM, Di Meglio D. Functional evaluation of tubularized-incised plate repair of midshaft-proximal hypospadias using uroflowmetry. *BJU Int*. 2001; 87(6): 540-3.
35. Tuygun C, Bakirtas H, Gucuk A, Cakici H, Imamoglu A. Uroflow findings in older boys with tubularized incised-plate urethroplasty. *Urol Int*. 2009; 82(1): 71-6.
36. Holmdahl G, Karström L, Abrahamsson K, Doroszkiewicz M, Sillén U. Hypospadias repair with tubularized incised plate. Is uroflowmetry necessary postoperatively? *J Pediatr Urol*. 2006; 2(4): 304-7.
37. Andersson M, Doroszkiewicz M, Arfwidsson C, Abrahamsson K, Holmdahl G. Hypospadias repair with tubularized incised plate: Does the obstructive flow pattern resolve spontaneously? *J Pediatr Urol*. 2011; 7(4): 441-5.
38. González R, Ludwikowski BM. Importance of urinary flow studies after hypospadias repair: a systematic review. *Int J Urol*. 2011; 18(11): 757-61.
39. Steckler RE, Zaontz MR. Stent-free Thiersch-Duplay hypospadias repair with the Snodgrass modification. *J Urol* 1997; 158(3 Pt 2): 1178-80.
40. Smith DP. A comprehensive analysis of a tubularized incised plate hypospadias repair. *Urology*. 2001; 57(4): 778-81.
41. Kalantari M, Mousavi SA, Ahmadi J, Nahvi H, Poorang H and Mehrabi V. The primary results of tubularized incised plate hypospadias repair in Markaz Tebbi and bahrami hospital. *Tumj*. 2005; 63(2): 120-23. [Persian]
42. Ritch CR, Murphy AM, Woldu SL, Reiley EA, Hensle TW. Overnight urethral stenting after tubularized incised plate urethroplasty for distal hypospadias. *Pediatr Surg Int*. 2010; 26(6): 639-42.