

Non-Surgical Management of Ductal Dependent Lesion as a Safe Option: A Case Report and Review of Literature

Prem Alva¹ and Aswathy Rajan^{2,*}

¹Department of Cardiology, AJ Hospital and Research Centre, Mangalore, India

²Department of Pediatrics, AJ Institute of Medical Sciences, Mangalore, India

*Corresponding author: Aswathy Rajan, Department of Pediatrics, AJ Institute of Medical Sciences, Mangalore, India. Tel: +91-8123550952, Fax: +91-8242225541, E-mail: ar_aswathy@yahoo.com

Received: April 21, 2015; Revised: May 30, 2015; Accepted: June 14, 2015

Introduction: Critical congenital heart disease with ductal dependent pulmonary blood flow can present in early neonatal period as a cardiac emergency.

Case Presentation: We herein reported a case of critical pulmonary stenosis in a newborn who presented with cyanosis and breathlessness.

Conclusions: Initially managed with prostaglandin, an emergency balloon pulmonary valvuloplasty proved to be an effective and safe option.

Keywords: Ductal Dependency; Balloon Valvotomy; Valvular Pulmonic Stenosis

1. Introduction

Congenital cardiac anomalies have an incidence of 8-10 cases per 1000 live births (1, 2). Many of the critical congenital heart diseases are ductal dependent. As a result, the affected neonate may not be symptomatic at birth, because the ductus arteriosus has not closed during the hospital stay. Ductal patency can initially provide clinical stability, but later they become tachypneic from the pulmonary over-circulation. Ductal dependent lesions depend on the patent duct for systemic or pulmonary flow. Once it begins to close, their survival and outcome is compromised unless prostaglandin E₁ is started (3).

2. Case Presentation

A two-day-old baby girl (weight: 2.4 kg) was brought to our hospital with a history of cyanosis and difficulty in breathing. Saturation was 30% in room air and 62% with supplemental oxygen. Heart rate was 168 beats per minute; respiration was 56 per minute and blood pressure 68.37 mm of Hg. On auscultation, a pulmonary ejection click and a continuous murmur were present, best heard below the clavicle. Echocardiography revealed critical pulmonary stenosis with moderate secundum atrial septal defect with right to left shunt with small patent ductus arteriosus with left to right shunt. There was a trickle of antegrade flow across the pulmonary valve (Figures 1 and 2). There was evidence of severe right ventricular hypertrophy. Findings were of a ductal dependent pulmonary circulation and hence prostaglandin E₁ (PGE₁) infusion was started at 0.05 mcg/kg/min along with dobutamine at 5 mcg/kg/minute.

The baby was intubated and taken up for an emergency balloon pulmonary valvuloplasty under general anesthesia in the cardiac catheterization laboratory. A catheter of 5Fr was introduced via the femoral vein and serial dilatation of pulmonary valve was performed with 1.5 × 10 mm, then 4 × 12 mm and 6 × 17 mm low pressure balloons. Right ventricular pressure reduced to 26/10 mm of Hg. Saturation of the baby improved to 88%. Post-procedure echocardiography showed gradient across pulmonary valve as 12 mmHg, mild pulmonary regurgitation, bi-directional shunt across the atrial septal defect and left to right shunt across the patent ductus arteriosus. The baby was supported with mechanical ventilation. However, due to right ventricular dysfunction, PGE₁ was continued and milrinone infusion was initiated.

On post-procedure day 3, the baby had an episode of desaturation. A repeat echocardiography showed evidence of persistent pulmonary artery hypertension and right ventricular dysfunction for which magnesium sulfate infusion was started. FiO₂ increased from 60% to 80%, rate was kept at 30 and the peak inspiratory pressure was lowered to 15. Oral sildenafil was started at a dose of 1 mg/kg. The saturation increased to 90% and the baby's condition improved thereafter. She was extubated by post-operative day 5 and inotropic support, PGE₁, magnesium sulfate and milrinone were gradually tapered and stopped by postoperative day 10. Baby recovered completely and was discharged two weeks after the procedure with oral sildenafil and furosemide.

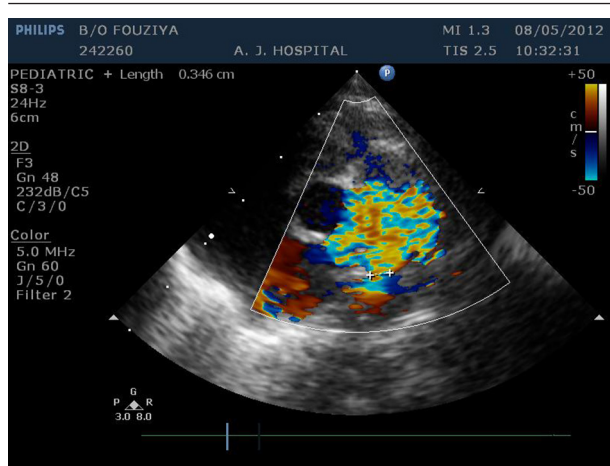


Figure 1. Echocardiographic Doppler Image Depicting Turbulent Flow Across Stenotic Valves

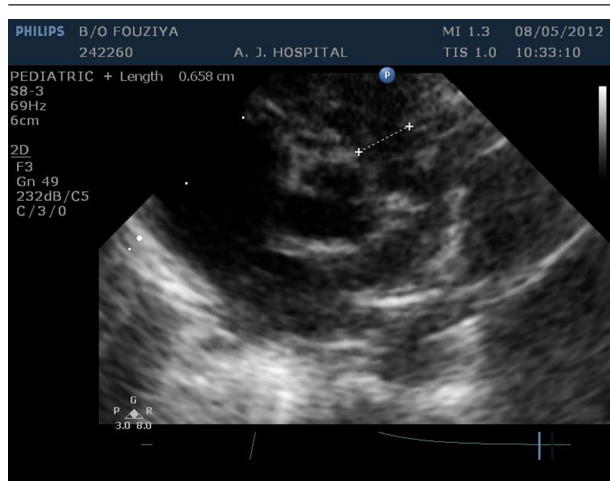


Figure 2. Echocardiographic Image Showing Doming Pulmonary Valve

3. Discussion and Review of Literature

Isolated pulmonary valve stenosis is seen in 0.33/1000 newborns, which constitutes 7 - 10% of all congenital heart diseases in children (4). Of various forms of right ventricular outflow obstruction, critical pulmonary stenosis is one of the most common forms. Often described as pulmonary stenosis with a pinhole orifice, critical pulmonary stenosis is severe pulmonary stenosis with right ventricular dysfunction or that associated with duct dependence (5, 6). Once diagnosed, it has to be treated as an emergency either surgically or non-surgical intervention.

A newborn with critical pulmonary valve stenosis develops cyanosis in the first few days of life with difficulty in feeding and breathlessness. Increasing cyanosis largely unresponsive to supplemental oxygen is due to diminished volume of blood flow into the lungs. Once the diagnosis of critical pulmonary valve obstruction is made echocardiographically, intravenous PGE₁ is administered to reopen the patent ductus arteriosus and restore pulmonary blood flow. There are several reports confirming the efficacy of PGE₁ in infants with ductal dependent congenital heart disease and it is indicated for all infants born with ductal dependent cardiac malformations. Usually given by intravenous infusion, it is started at an initial dose of 0.05 - 0.2 mcg/kg/minute. Once the desired effect is attained, then the dose is tapered to 0.01 - 0.025 mcg/kg/minute (7).

Since its introduction by earlier study, balloon pulmonary valvuloplasty (BPV) is the procedure of choice in critically ill neonates (5). Over the years, many studies have been conducted showing the success rate of BPV in many centers (Table 1) (8). Immediate reduction in pressure gradient can be achieved in more than 90% of these neonates, but some of these infants are not able to maintain effective forward flow through the pulmonary valve because of noncompliant or hypoplastic right ventricle, requiring surgical intervention. If ductal dependence persists, a Blalock Taussig shunt operation is indicated (6).

Table 1. Review Articles and Case Reports Showing Success Rate of BPV in Critical Pulmonary Stenosis

Authors	Year	No. of Cases	Successful BPV, %	Patients Requiring Consequent Surgery/Complication/Death
Smolinsky et al. (9)	1992	38	78.9	8
Burzynski et al. (10)	1993	8	100	1
Lee et al. (11)	2008	27	92.5	2
Werynski et al. (4)	2009	137	97.6	5
Saad et al. (12)	2010	76	85	11
Al-Madani (13)	2010	132	66	45
Bandara et al. (14)	2011	94	55.7	51
Nakhostin et al. (15)	2011	78	43	44
Maostafa et al. (16)	2012	60	88.3	6
Ahmadi and Sabri (17)	2012	34	85	5
Ghaffari et al. (18)	2012	87	78.2	19
Sharma et al. (19)	2012	122	99.9	1
Parent and Hoyer (20)	2013	23	65	8

BPV has now supplanted surgical valvotomy as the first line procedure of choice in institutes with trained interventional cardiologists. Percutaneous femoral venous access is the most preferred route for BPV (5). Transumbilical route has also been successfully used in neonates (7). A significant number of newborns may not maintain saturations after the procedure. This is mainly due to right ventricular diastolic dysfunction (which determines the shunt flow across the atrial septum and not the systolic function), which may take several days to few weeks to regress. Apart from right to left shunt causing desaturation, there may be a problem related to adequate cardiac output not being maintained due to severe right ventricular hypertrophy resulting in a significantly lowered end diastolic volume. In that situation, the cardiac output needs to be maintained by keeping the duct open (21). Transient bradycardia and ST elevation while crossing right ventricular outflow tract and moderate pulmonary regurgitation have been noted (22).

The outcome after balloon or surgical valvotomy is generally excellent with less than 10% patients requiring a repeat procedure (21). The probability of survival is similar to that of the general population and most patients are asymptomatic (1). However, in neonates, complications of the balloon procedure are more common than older patients, with a mortality rate of up to 3%, a major complication rate of 3.5% and a minor complication rate of 15%. Even dysplastic valves appear to mature after the procedure. Some patients require re-intervention (either repeated valvuloplasty or surgery) at a later time if pulmonary stenosis progresses in severity (6).

References

- Hoffman JIE, Kaplan S. The incidence of congenital heart disease. *J Am College Cardiol.* 2002;**39**(12):1890-900.
- Kaemmerer H, Hess J. [Adult patients with congenital heart abnormalities: present and future]. *Dtsch Med Wochenschr.* 2005;**130**(3):97-101.
- Altman CA. *Congenital heart disease (CHD) in the newborn: Presentation and screening for critical CHD.* 2012. Available from: <http://www.uptodate.com/contents/congenital-heart-disease-chd-in-the-newborn-presentation-and-screening-for-critical-chd>.
- Werynski P, Rudzinski A, Krol-Jawien W, Kuzma J. Percutaneous balloon valvuloplasty for the treatment of pulmonary valve stenosis in children - a single centre experience. *Kardiol Pol.* 2009;**67**(4):369-75.
- Bilkis AA, Alwi M, Hasri S, Geetha K, Law HI. Critical Pulmonary Stenosis in Infants and Neonates in the Era of Interventional Cardiology. *Asian Cardiovasc Thorac Ann.* 1999;**7**(1):40-5.
- Park MK. *Paediatric cardiology for practitioners.* Philadelphia: Mosby Inc.; 2008. pp. 242-7.
- Kim GB, Bae EJ, Noh CI. Balloon valvuloplasty for neonatal critical pulmonary valvar stenosis with IVC interruption: pitfalls of the transumbilical approach. *J Korean Med Sci.* 2010;**25**(3):485-8.
- Kohli V. Neonatal cardiac interventions: an Indian perspective. *Indian J Pediatr.* 2009;**76**(2):207-14.
- Smolinsky A, Arav R, Hegesh J, Lusky A, Goor DA. Surgical closed pulmonary valvotomy for critical pulmonary stenosis: implications for the balloon valvuloplasty era. *Thorax.* 1992;**47**(3):179-83.
- Burzynski JB, Kveselis DA, Byrum CJ, Kavey RE, Smith FC, Gaum WE. Modified technique for balloon valvuloplasty of critical pulmonary stenosis in the newborn. *J Am Coll Cardiol.* 1993;**22**(7):1944-7.
- Lee ML, Peng JW, Tu GJ, Chen SY, Lee JY, Chang SL. Major determinants and long-term outcomes of successful balloon dilatation for the pediatric patients with isolated native valvular pulmonary stenosis: a 10-year institutional experience. *Yonsei Med J.* 2008;**49**(3):416-21.
- Saad MH, Roushdy AM, Elsayed MH. Immediate- and medium-term effects of balloon pulmonary valvuloplasty in infants with critical pulmonary stenoses during the first year of life: A prospective single center study. *J Saudi Heart Assoc.* 2010;**22**(4):195-201.
- Al-Madani A. Mid-term results of balloon pulmonary valvuloplasty in children at Queen Alia Heart Institute. *J Royal Med Serv.* 2010;**17**(2):47-52.
- Bandara SI, Narenthiran S, Santharaj W, Rajakanthan K, Samarasinghe D, Perera S, et al. Short term results of balloon pulmonary valvuloplasty in children: a single centre study over a period of 42 months. *Sri Lanka J Child Health.* 2011.
- Nakhostin DP, Mortezaian LH, Ghaemi HR. The evaluation of late outcome of balloon pulmonary valvuloplasty in children. *Tehran Univ Med J.* 2011;**68**(9).
- Maostafa BA, Seyed-Hossien M, Shahrokh R. Long-term Results of Balloon Pulmonary Valvuloplasty in Children with Congenital Pulmonary Valve Stenosis. *Iran J Pediatr.* 2013;**23**(1):32-6.
- Ahmadi A, Sabri M. Percutaneous balloon valvuloplasty in patients with pulmonary valve stenosis: a single center experiment. *J Pak Med Assoc.* 2012;**62**(3 Suppl 2):S58-61.
- Ghaffari S, Ghaffari MR, Ghaffari AR, Sagafy S. Pulmonary valve balloon valvuloplasty compared across three age groups of children. *Int J Gen Med.* 2012;**5**:479-82.
- Sharma R, Rajbhandari R, Limbu Y, Singh S, Bhatt YKD. Balloon Pulmonary Valvotomy in children with Congenital Valvular Pulmonary Stenosis. *Nepal Heart J.* 2012;**9**(1):7-9.
- Parent JJ, Hoyer MH. Delayed success of balloon dilation for co-existing pulmonary valve stenosis and sinotubular narrowing. *Congenit Heart Dis.* 2014;**9**(3):216-20.
- Saxena A, Sharma M, Kothari SS, Juneja R, Reddy SC, Sharma R, et al. Prostaglandin E1 in infants with congenital heart disease: Indian experience. *Indian Pediatr.* 1998;**35**(11):1063-9.
- Hoffman JI. It is time for routine neonatal screening by pulse oximetry. *Neonatology.* 2011;**99**(1):1-9.